

Chapter 32A

Abdominal Hysterectomy

Howard W. Jones III

DEFINITIONS

Incidental oophorectomy—When clinically normal ovaries are removed at the time of a hysterectomy. This is an older term. *Prophylactic oophorectomy* is now preferred.

Prophylactic oophorectomy—The preferred term for removing clinically normal ovaries at the time of hysterectomy. This terminology emphasizes the risk reduction of ovarian and possibly breast cancer as a result of oophorectomy.

Supracervical hysterectomy—Also referred to as a *subtotal hysterectomy*. This operation removes the uterine fundus, transecting the upper portion of the cervix below the level of the uterine vessels. The cervix is left in situ.

Trendelenburg position—With the patient on the operating table in the supine position, the head is lowered below the level of the pelvis.

Hysterectomy is the most common operation performed by the gynecologist, and it is the second most common major surgical procedure done in the United States. Only cesarean section is more common. There are many indications for hysterectomy, and the uterus can be removed using any of a variety of techniques and approaches, including abdominal, vaginal, laparoscopic, and, more recently, robotic hysterectomy. In most cases, a total hysterectomy with removal of the uterine corpus and cervix is done; but in recent years, there has been a resurgence in the popularity of supracervical hysterectomy. The ovaries and tubes may or may not be removed along with the uterus, depending on the patient's age and a variety of other factors. The gynecologic surgeon not only should be technically adept at these various procedures but also should use history, physical examination, and discussion with the patient to match the surgical procedure to the patient to obtain the most satisfactory outcome.

The three sections of this chapter discuss abdominal, vaginal, and laparoscopic hysterectomy. Robotically assisted hysterectomy or robotic hysterectomy is discussed in [Chapter 17](#) on Robotic Surgery.

HISTORY

The history of hysterectomy is long and varied. Although significant advances in the technique of hysterectomy did not occur until the 19th century, earlier attempts are known. Some references to hysterectomy even date to the fifth century bc, in the time of Hippocrates. The earliest attempts at removal of the uterus were made vaginally for indications of uterine prolapse or uterine inversion. By the 16th century, a number of hysterectomies already had been done in Europe, including Italy, Germany, and Spain. In 1600, Schenck of Grabenberg cataloged 26 cases of vaginal hysterectomy.

Vaginal hysterectomies were done sporadically through the 17th and 18th centuries. In 1810, Wrisberg presented a paper to the Vienna Royal Academy of Medicine recommending vaginal hysterectomy for uterine cancer. Three years later, the German surgeon Langenbeck successfully performed a vaginal hysterectomy for uterine cancer. The first vaginal hysterectomy performed in the United States was in 1829 by John Collins Warren at Harvard University; however, the patient expired on the fourth postoperative day. Three years following Warren's attempt, Herman and Werneberg in Pittsburgh successfully performed a vaginal hysterectomy

for uterine cancer. By the late 19th century, techniques for vaginal hysterectomy were systematically studied and developed by Czerny, Billroth, Mikulicz, Schroeder, Kocher, Teuffel, and Spencer Wells.

The earliest abdominal hysterectomy attempts usually involved uterine leiomyomata that had been misdiagnosed as ovarian cysts. In the early 19th century, laparotomy for ovarian cysts still was considered dangerous, despite initial successes by McDowell in the United States and Emiliami in Europe in 1815. Abdominal hysterectomy for any reason was considered impossible to accomplish successfully. Many of the earliest myomectomies involved pedunculated tumors. Washington L. Atlee of Lancaster, Pennsylvania, performed the first successful abdominal myomectomy in 1844; although in a series of 125 surgeries, he did not attempt to remove the uterus.

The first reported abdominal hysterectomy was attempted by Langenbeck in 1825. The 7-minute operation for advanced cervical cancer resulted in the patient's demise several hours later. Abdominal surgery was commonly complicated by postoperative hemorrhage that was often lethal. In the mid-19th century, an English surgeon, A.M. Heath from Manchester, was the first to ligate the uterine arteries, but it would be nearly 50 years before his technique became common practice.

P.698

Successful surgery depends on control of bleeding, infection, and pain. Ligatures were known to be used to tie off bleeding vessels as early as 1090, and artery forceps were invented in the mid-16th century by Ambroise Pare. However, information regarding the pathophysiology of hemorrhage, shock, and blood transfusions was not available until the 20th century. The importance of infection control was first recognized by Austrian Ignaz Semmelweiss in his work with childbed fever. His 1840s work was furthered by Joseph Lister in the 1860s and aided by notable discoveries by Louis Pasteur and Robert Koch.

It was not until 1864 that the Frenchman Koeberle introduced his method of securing the large vascular pedicle of the lower uterus with his tool, the serrenoeud. This ligature en masse around the lower uterus with the corpus amputated above was the usual technique of controlling bleeding with hysterectomy in the earliest years. The stump thus formed was such a large mass of tissue that it could not always be safely returned to the peritoneal cavity owing to risk of intraperitoneal bleeding; often, the stump was fixed extraperitoneally in the incision so that it could be clamped later if necessary.

American Crawford W. Long first used ether as anesthesia in 1842, and Scotsman Sir James Y. Simpson initiated the use of chloroform in his obstetric practice. W.A. Freund of Germany further refined hysterectomy techniques in 1878 using anesthesia, antiseptic technique, Trendelenburg position, and ligature around ligaments and major vessels. The bladder was dissected from the uterus, and the cardinal and uterosacral ligaments were detached; the pelvic peritoneum then was closed. Late in the 19th century, further refinements were made to abdominal hysterectomy techniques by the surgeons of the Johns Hopkins Hospital, where they reduced their mortality to 5.9%.

In the early decades of the 20th century, hysterectomy became more commonly used as treatment for gynecologic disease and symptoms. Gynecology as a specialty was developing, and little else but surgery was available to gynecologists to help their patients. Major discoveries and concepts of reproductive organ physiology and pathology were just beginning. Estrogen and progesterone were not discovered until the late 1920s and early 1930s.

As gynecology matured as a specialty, knowledge of reproductive organ function and disease became more complete. Special and more accurate diagnostic techniques were developed, and effective nonsurgical methods of therapy were discovered. In the modern practice of gynecology, appropriate use of this knowledge and advanced modern diagnostic technologies allow more accurate diagnosis, and conditions such as uterine fibroids or abnormal uterine bleeding, which used to be treated primarily by surgery, can now often be managed with hormones or other medications. In addition, surgical techniques have evolved and minimally invasive or

even noninvasive approaches to uterine pathology have been developed. Focused ultrasound destruction of uterine fibroids and vascular embolization of fibroids are two examples of modern techniques (done primarily by radiologists) that have replaced traditional gynecologic surgical procedures.

Advances in anesthetic techniques, blood transfusions and fluid management, and the use of prophylactic antibiotics have made surgery safer and appropriate for more women with medical comorbidities. But the gynecologic surgical procedures themselves have changed significantly in the modern era. Laparoscopy, hysteroscopy, and robotically assisted techniques have added new technology to manage gynecology pathology and new platforms to accomplish a hysterectomy.

INCIDENCE

Hysterectomy is a very common surgical procedure. In the United States, more than half a million women undergo hysterectomy each year, and it is estimated that by age 65, one third of women in this country will have had their uterus surgically removed. Annual medical costs related to hysterectomy exceed \$5 billion in the United States. However, there are significant variations in hysterectomy rates within the United States and throughout the world. In a study from the Kaiser health care plan in California, Jacobson and colleagues reported an overall hysterectomy rate of 3.41 per 1,000 women older than age 20 in 2003. This is similar to but somewhat lower than the rate of 4.7 per 1,000 women reported from Olmsted County, Minnesota, from 1995 to 2002. In a nationwide sample, Farquhar and Steiner reported an overall hysterectomy rate of 5.6 per 1,000 women in the United States in 1997. In Western Australia, Spilsbury and colleagues recently reported an agestandardized rate of 4.8 per 1,000 women. In Italy, Mataria has reported a rate of 3.7, and a very low rate of 1.2 per 1,000 eligible women was reported from Norway.

This variation in rates from one location to another is due to several factors, including patient expectations and availability of medical care. But it is primarily related to the training and practice patterns of the local gynecologic surgeons. In some areas, abnormal uterine bleeding may be managed primarily by hormonal therapy, whereas in other locations, hysterectomy may be quickly recommended. Alternatives to hysterectomy have decreased the rate of hysterectomy in recent years. Systemic hormonal therapies have been effective for managing menorrhagia; recently, a progestational intrauterine system has been shown to be similarly effective. Intrauterine thermal balloons, microwave, and electrical instruments are all effective outpatient techniques for endometrial ablation as an alternative to hysterectomy for symptomatic uterine bleeding. Leiomyomata can now be treated with transcervical hysteroscopic resection and also by transcatheter uterine artery embolization. These new management techniques, together with an overall desire to decrease the use of major surgery, have decreased the use of hysterectomy in recent years.

In addition, today's gynecologic surgeon has several techniques for hysterectomy from which to choose. Although abdominal hysterectomy is still the most commonly used approach, there has been a definite increase in the use of both vaginal and laparoscopic hysterectomy in recent years. [Table 32A.1](#) shows

P.699

the frequency of the various techniques in recent reports from around the world. For the first time, this edition of the hysterectomy chapter is subdivided into sections on abdominal, vaginal, and laparoscopic hysterectomy. In this section, we concentrate on the abdominal approach to hysterectomy.

TABLE 32A.1 Worldwide Comparison of Hysterectomy Technique

ABDOMINAL (%)	VAGINAL (%)	LAPAROSCOPIC (%)
---------------	-------------	------------------

USA, nationwide	63	29	11
USA, California	71	25	4
USA, Minnesota	44	56	<1
England	75	23	1.4
Australia	40	45	15
Denmark	80	14	6
Finland	58	18	24

INDICATIONS FOR HYSTERECTOMY

Table 32A.2 lists commonly accepted indications for hysterectomy. As discussed above, a variety of new surgical and nonsurgical techniques or treatments are now available to manage many of the symptoms or conditions for which hysterectomy has been required in the past. These approaches are often a compromise. Alternative management approaches may be less invasive, less morbid, and possibly less expensive, but symptoms, although improved, may persist. Eventually, hysterectomy may be elected as a secondary management option for some patients, such as those who continue to have more bleeding than they are willing to tolerate after transcervical endometrial ablation.

In some cases, hysterectomy may be done in conjunction with other abdominal procedures, such as removal of a benign or malignant ovarian tumor or treatment of chronic pelvic inflammatory disease or endometriosis. There may be no pathologic changes in such a uterus, and some have contended that these are examples of an “unnecessary hysterectomy.” This is certainly not true, but it is important that the surgeon clearly explain why the uterus is being removed as a part of the surgical procedure. Because abdominal hysterectomy is the most common major gynecologic operation done in the United States, it is under careful scrutiny by a variety of regulatory agencies and public health care policy groups. The surgeon should carefully evaluate each patient and consider the diagnosis and management options before recommending hysterectomy and, specifically, abdominal hysterectomy. Numerous studies have shown that women who have undergone hysterectomy show a significant improvement in their quality-of-life indices. But care must be taken to make the correct diagnosis, be sure that the patient's condition will benefit from hysterectomy, and recommend the most appropriate type of hysterectomy for that specific patient.

TABLE 32A.2 Indications for Hysterectomy

BENIGN DISEASE	MALIGNANT DISEASE
Abnormal bleeding	Cervical intraepithelial neoplasm
Leiomyoma	

Adenomyosis	Invasive cervical cancer
Endometriosis	Atypical endometrial hyperplasia
Pelvic organ prolapse	Endometrial cancer
Pelvic inflammatory disease	Ovarian cancer
	Fallopian tube cancer
Chronic pelvic pain	Gestational trophoblastic tumors
Pregnancy-related conditions	

The late Richard W. Te Linde, professor of gynecology at the Johns Hopkins University and the original author of this text, wrote:

The ease with which the average hysterectomy may be done has proven both a blessing and a curse to womankind. There is no doubt that a hysterectomy done with proper indications may restore a woman to health and even save her life. However, in the practice of gynecology, one has ample opportunity to observe countless women who have been advised to have hysterectomies without proper indications ... I am inclined to believe that the greatest single factor in promoting unnecessary hysterectomies is a lack of understanding of gynecologic pathology. The greatest need today among those who are performing pelvic surgery is a better knowledge of gynecologic pathology.

CHOICE OF APPROACH: ABDOMINAL, VAGINAL, OR LAPAROSCOPIC

Today, there are many different approaches to hysterectomy. The uterus can be removed via the abdominal route, transvaginally, or laparoscopically. Combinations of several techniques can be selected, such as a laparoscopically assisted vaginal hysterectomy. Although abdominal hysterectomy continues to be the most common approach used worldwide, there is good evidence from multiple randomized, prospective trials that vaginal and laparoscopic hysterectomies are associated with fewer complications, a shorter hospital stay, a more rapid recovery, and lower overall costs ([Table 32A.3](#)). In addition, Kovac and others have shown that most patients who require hysterectomy can have it performed vaginally. Who, then, is a proper candidate for an abdominal hysterectomy? Most patients with gynecologic malignancy are still operated on with an abdominal incision. Although this will undoubtedly continue to be true for women with ovarian cancer who frequently have extensive pelvic and upper abdominal metastases, laparoscopic techniques and more recently robotic surgical techniques are being used more and more frequently in women with endometrial and cervical cancer.

Another indication for abdominal hysterectomy is a large uterus that prevents safe and reasonable vaginal hysterectomy. This is obviously very dependent on the skills and experience of the surgeon, because there are various techniques that allow a very large benign uterus to be removed from below. Nevertheless, most gynecologists would agree that a uterus larger than 12 weeks' gestational size is a reasonable size to qualify for an abdominal approach. The shape and size of the pelvic outlet are also key factors. Although the degree of prolapse is not an absolute factor, patients with limited uterine prolapse are more difficult to do transvaginally. Cervical fibroids or cervical enlargement for any reason may compromise vaginal exposure and make it difficult to

place clamps laterally.

An unknown adnexal mass, extensive pelvic endometriosis, or adhesions from prior surgery or pelvic infection may also be an indication for an open abdominal approach including a hysterectomy. In some cases, a diagnostic laparoscopy will clarify the situation and may allow the procedure to be converted to a laparoscopically assisted vaginal hysterectomy. A careful preoperative evaluation—starting with a thoughtful history and physical examination and supplemented, where indicated, by imaging studies such as a pelvic ultrasound or computerized tomography scan of the pelvis and abdomen—will usually enable the gynecologist to decide on the most appropriate type of hysterectomy. The diagnosis and reason for the approach selected should be thoroughly explained and discussed with the patient and any appropriate family or friends. In rare cases, the final decision concerning the type of hysterectomy will depend on the findings of the exam under

P.700

anesthesia or the findings at laparoscopy. In those cases, all the “what ifs ...” should be carefully reviewed with the patient before the surgery and the family kept informed as decisions are made during the operation.

TABLE 32A.3 Characteristics of Hysterectomy by Different Approaches

	ABDOMINAL	VAGINAL	LAPAROSCOPICALLY ASSISTED VAGINAL
Number of patients	1,184	530	839
Uterine weight (average)	216 g	113 g	129 g
Operative time (average)	82 min	63 min	102 min
Blood loss ^a (average)	5.35%	5.19%	6.0%
Complications			
Fever 101 °F	9.1%	3.2%	2.0%
Transfused	2.5%	0.9%	0.6%
Bowel, bladder, or ureteral injury	1.0%	0.9%	0.7%
Death	0	1	0
Hospital stay	60 h	40 h	40 h
Hospital charges	\$6,552	\$5,879	\$6,431

^aBlood loss is percent change in preoperative versus postoperative hematocrit.

From Johns DA, Carrera B, Jones J, et al. The medical and economic impact of laparoscopically

assisted vaginal hysterectomy in a large, metropolitan, not-for-profit hospital. *Am J Obstet Gynecol* 1995;172:1709, with permission.

Subtotal versus Total Hysterectomy for Benign Conditions

In the United States, and throughout most of the world, hysterectomy—whether done transvaginally or through an abdominal incision—usually includes removal of the cervix. Over the past 50 years, subtotal or supracervical hysterectomy has come to be viewed as a suboptimal procedure reserved for those rare instances when concern over blood loss or anatomic distortion dictates limiting the extent of dissection.

More recently, however, the routine practice of removing the cervix at the time of hysterectomy for benign disease is now being challenged as many traditional surgical procedures are being modified to accommodate minimally invasive techniques. Total laparoscopic hysterectomy has been associated with an increased risk of ureteral and bladder injury so that laparoscopic supracervical hysterectomy has been introduced to avoid these complications. The introduction of a powered laparoscopic tissue morcellator has allowed gynecologic surgeons to perform a supracervical hysterectomy rapidly and efficiently, even on an enlarged uterus. The rapidity of the procedure, the quick postoperative recovery, and the popularity of cervical preservation among the lay public have now resulted in an increased use of abdominal supracervical hysterectomy.

In a study from California involving almost 650,000 women who underwent hysterectomy between 1991 and 2004, Smith et al. reported that the incidence of subtotal, supracervical hysterectomy increased from negligible to 21% of all hysterectomies in 2004. It is doubtful that this technique is as common in other regions of the United States and throughout the world, but the advantages of speed and a low complication rate plus the reduced risk of cervical cancer in the retained cervix due to improved screening and conservative management of cervical intraepithelial neoplasia make supracervical hysterectomy attractive to many patients and surgeons.

There is clearly a market for this procedure, but all of the recent prospective, randomized trials have not found any longterm advantage of supracervical abdominal hysterectomy compared with total abdominal hysterectomy. However, several recent prospective, randomized studies in the United States and abroad have shown no difference in sexual satisfaction, bowel or bladder function, or vaginal prolapse after simple total hysterectomy compared with supracervical hysterectomy for benign disease. My own clinical experience over 30 years also confirms this impression.

Management of Normal Ovaries

Should normal ovaries be removed at the time of hysterectomy for benign disease? The term *prophylactic oophorectomy* is preferred when referring to the removal of clinical normal ovaries at the time of hysterectomy. The use of *incidental oophorectomy* is not recommended because it suggests that an oophorectomy is done without planning or consideration and has no consequences. There is no doubt that bilateral oophorectomy reduces the risk of ovarian cancer and the need for future surgery for benign conditions of the ovaries. However, the ovaries continue to produce low levels of androgens even after the menopause, and although the benefits, if any, of this hormone production are unknown, the psychological effect of oophorectomy on some women is significant.

Prophylactic oophorectomy is done in 50% to 66% of women aged 40 to 65 who undergo hysterectomy in the United States. Averette and Nguyen have estimated that 1,000 of the approximately 24,000 new cases of ovarian cancer in the United States would be prevented if prophylactic bilateral salpingo-oophorectomy was done at the time of hysterectomy on all women older than age 40. In a more recent prospective cohort study of 30,117 women in the Nurses' Health Study, Parker et al. confirmed a very significant risk reduction in death from ovarian cancer and death from breast cancer for those women who underwent bilateral oophorectomy before age 47.5

years. However, they also observed that there was a significant (1.15 hazard ratio) increased risk of death from all causes in those women who underwent bilateral oophorectomy before age 50. This increased risk of death from all causes (especially cardiovascular disease and lung cancer) was not observed in those women who used estrogen replacement therapy. The significance and implications of these findings have been discussed and questioned, but it is clear that while removing the ovaries and fallopian tubes will decrease the subsequent risk of

P.701

cancer of these organs, the hormonal effects of premenopausal oophorectomy have implications more life threatening than hot flashes or night sweats. It behooves the gynecologic surgeon to keep up with this ongoing controversy so that we can counsel our patients based on the most recent facts and concepts.

Clearly, there are some significant potential benefits to oophorectomy at the time of any pelvic surgery in women with a known BRCA1 or BRCA2 gene mutation, a strong family history of ovarian or breast cancer, or women of Eastern European Jewish heritage. Recent studies also have clearly shown a decrease in the risk of breast cancer in women who have undergone bilateral oophorectomy. This is of particular importance in women from families with a history of ovarian or breast cancer and those with known BRCA gene mutations. In a series of 177 women with BRCA1 or BRCA2 mutations who were enrolled prospectively and followed for up to 6 years, Kauf and associates reported a 4% incidence of breast cancer among the 69 women who underwent prophylactic oophorectomy compared with a 13% incidence among those who elected follow-up surveillance only. In a similar retrospective review of 259 women compared with matched controls, the risk of breast cancer was reduced by 50% in the women who had bilateral oophorectomy. In both series, the risk of peritoneal or ovarian cancer was decreased by 95%. In a follow-up study of 4,931 women who underwent hysterectomy without oophorectomy at 10, 20, and 30 years with a control group of women who had not had hysterectomy, the risk of additional surgery to remove the ovaries was 3.5% (1.9% rate of oophorectomy in the women who had not has a hysterectomy). By 20 years, 6.2% of the women who had previously undergone hysterectomy had required oophorectomy, and by 30 years, 9.2% had undergone oophorectomy. Removing one ovary at the time of hysterectomy did reduce the risk of subsequent surgery for oophorectomy, but even without any pelvic surgery, 7.3% of the age-matched control group required oophorectomy during 30 years of follow-up.

Four case-control studies that found a lower risk of ovarian cancer among women who had a history of previous hysterectomy with ovarian conservation have been analyzed by Weiss and Harlow. The authors felt the reduction in ovarian cancer risk was explained by incidental screening for visible ovarian malignancy at the time of hysterectomy in those women in whom the ovaries are not removed. Those women with grossly normal ovaries have a reduced risk of developing symptomatic ovarian cancer over the next few years. In a large, prospective cohort study of 238,130 married, female nurses in the United States, Rice et al. found that hysterectomy was associated with a 20% reduction in the rate of subsequent ovarian cancer. Tubal ligation resulted in a 24% decreased risk of ovarian cancer. Unilateral oophorectomy was found to reduce the risk of ovarian cancer by 30%. The mechanism by which hysterectomy and tubal ligation reduce ovarian cancer is not known, but it is possible that the interruption of the pathway of unknown pathogens from the vagina to the ovary may be involved.

Traditionally, many gynecologists have recommended against prophylactic oophorectomy in women younger than the age of 40 and offered oophorectomy to postmenopausal women. There is no consensus for the management of women between 40 and 50. There are no data to support these approaches. It seems reasonable to discuss the possibility of oophorectomy before planned hysterectomy for benign disease in women older than age 45. However, it should be made clear to those women that there are some definite disadvantages to oophorectomy, especially if they will not or cannot use estrogen replacement therapy postoperatively. Each patient brings her own ideas and experiences to this discussion, and the surgeon should try to counsel the

patient and her family so she will be happy with her decision about oophorectomy.

PREOPERATIVE COUNSELING

The gynecologist needs to talk with the patient while trying to decide whether a hysterectomy is indicated. Fortunately for the patient and the gynecologist, time for talking is available in almost every instance. A hysterectomy is rarely an emergency. Unfortunately, the time may not be used properly. In a survey of women who underwent hysterectomy, Neefus and Taylor found that there is an urgent need for patient education on the physical, psychological, and sexual aspects of hysterectomy.

Often, the need for hysterectomy is obvious. There is a complete prolapse, or a large and symptomatic leiomyomatous uterus, or a pelvic cancer. However, under all circumstances, the indications for hysterectomy should be carefully explained. It is important that whenever possible, not only the patient but, in addition, her family and/or those who will support her during the perioperative period be involved in these discussions. The “informed consent” should be explained clearly and in language that the patient and her family can understand. Treatment alternatives should be discussed and the reasons for recommending one approach over another should be explained. The risks, benefits, and side effects, specifically including the possibility of transfusion, must be reviewed, but in such a way that the patient is not unduly alarmed. Then, the patient and the physician should spend the time necessary to discuss any questions that the patient or family may have. Additionally, the patient should be encouraged to ask questions about the operation: how long it will take, the recuperation period in the hospital and at home, whether ovarian function should be conserved, and possible hormone replacement therapy. Patient information pamphlets and videos also are useful for preoperative education. The expectations of the patient and her family are very important in her postoperative view of the success (or failure) of the operation.

Because the uterus is the main organ associated with reproduction, it is an important part of a woman's self-image; in some cultures, a woman's sexuality and reproductive potential are viewed as important parts of her value or status in her family or society as a whole. For these reasons, it is absolutely necessary for the gynecologic surgeon to understand and help patients cope with the emotional turmoil that may accompany hysterectomy. For some women who have had their children and need a hysterectomy for prolonged heavy bleeding and cramping associated with uterine fibroids or those with a diagnosis of endometrial cancer, the indications are clear, the benefits are obvious, and the loss of reproductive capacity often is not of great concern. The emotional stress of hysterectomy on these women is usually minimal, and psychological adjustment often is rapid and complete. However, the young woman needing a hysterectomy for cervical cancer or a complication of pregnancy may have considerable difficulty adjusting to the loss of her uterus. Even the 32-year-old woman with three children and severe uterovaginal prolapse may not be comfortable with the idea of hysterectomy. The gynecologist must be sensitive to these possible concerns and anxiety. Even when the patient does not express any emotional distress, the gynecologist can provide an opening for the patient to discuss her feelings by statements such as “Most studies have shown no change in sexuality and sexual function after hysterectomy, but I know many patients have concerns about this. Do you have any questions?” The support of the patient's husband or partner and her family and friends are very useful elements to prevent and manage depression and the emotional stress of hysterectomy. The wise surgeon includes members of this support group in preoperative discussions and encourages them to

P.702

ask questions or express opinions that actually may be questions or opinions of the patient that she may be hesitant to express.

Despite improvements in preoperative counseling in recent years, some women are depressed after hysterectomy. In most instances, this depression is short-lived and self-limiting, but the gynecologist should be

alert for severe or prolonged symptoms of continued lack of energy, inability to return to normal activities of daily living, sleep difficulties, or other indicators of depression following surgery. Occasionally, antidepressants and/or psychiatric consultation may be necessary. The psychological aspects of pelvic surgery are extensively reviewed in [Chapter 3](#).

PREPARATION FOR HYSTERECTOMY

A complete history and physical examination is indicated before any operative procedure. This evaluation is detailed in [Chapter 8](#), but a few points deserve emphasis. Although it is appropriate to ensure that all gynecologic symptoms have been evaluated carefully and a pelvic examination performed, a complete physical evaluation is necessary to be sure the patient can safely tolerate anesthesia and major surgery. Appropriate consultation should be sought where indicated to assure safe anesthesia administration and anticipation of any perioperative medical problems. In addition to a preoperative hematocrit or hemoglobin and other laboratory tests as indicated by the patient's medical condition, it is important to have a recent Pap or HPV test to rule out cervical neoplasia. A pregnancy test in reproductive-age women is recommended before surgery.

Preoperative chest x-rays are no longer routinely recommended but may be indicated in women with a history of cardiorespiratory disease or malignancy. An intravenous pyelogram, ultrasound, or computed tomography scan of the abdomen and pelvis may be useful in women with uterine or extrauterine pelvic masses, but these are not indicated routinely.

Mechanical bowel preparation before simple hysterectomy has been largely abandoned in recent years. However, when the uterus is large or extensive adhesiolysis is anticipated, we prefer to have the colon evacuated before pelvic surgery to facilitate exposure and reduce trauma to the bowel caused by retraction and packing. In these patients, we recommend a clear liquid diet on the day before surgery, and 250 mL of oral magnesium citrate is an effective laxative on the afternoon before surgery. A bisacodyl suppository immediately on arising on the morning of surgery will evacuate any residual feces or fluid in the sigmoid and prevent contamination of the field during surgery. A complete mechanical or antibiotic bowel preparation is indicated only when intestinal surgery is a possibility (see [Chapter 47](#)).

Surgical site infection risk is decreased by routine use of prophylactic intravenous antibiotics given approximately 30 minutes before the skin incision. First- or second-generation cephalosporins, such as cefazolin or cefoxitin, are commonly used. Recommended antibiotic regimens are shown in [Table 32A.4](#). Prospective, randomized trials have shown a significant reduction in the risk of febrile morbidity and infection in both abdominal and vaginal hysterectomy. Studies have shown no benefit of continuing antibiotics postoperatively, although a second dose of antibiotics generally should be given during hysterectomy procedures that last longer than 3 hours. Some have suggested that bacterial vaginosis increases the risk of postoperative infections after vaginal hysterectomy, but preoperative evaluation and treatment remain controversial. Although povidone-iodine douches and antibiotic scrubs before surgery have been widely used in the past, studies have shown no added benefit when perioperative intravenous antibiotics are employed.

TABLE 32A.4 Recommended Prophylactic Antibiotic Regimens for Hysterectomy

ANTIBIOTIC	DOSAGE	HALF-LIFE
Cefoxitin	2 g IV	0.5-1.1 h
Cefazolin	1-2 g IV	1.2-2.5 h

Cefotetan	1-2 g IV	2.8-4.6 h
For patients with an immediate sensitivity to penicillin		
Metronidazole ^a	1 g IV	6-14 h
OR		
Metronidazole ^b + gentamicin or a quinolone	1 g IV 1.5 mg/kg or 500 mg	
OR		
Clindamycin ^b	900 mg IV	2-5 h
IV, intravenously.		
^a American College of Obstetricians and Gynecologists. ACOG Practice Bulletin No. 74. <i>Antibiotic prophylaxis for gynecologic procedures</i> . Washington, DC: ACOG, 2006.		
^b Surgical Care Improvement Project recommendation, October 2006. Surgical Care Improvement Project. <i>Prophylactic antibiotic regimen selection for surgery</i> . Available at: http://www.medicqic.org/scip . Accessed April 16, 2007.		

If necessary, the pubic and/or vulvar hair should be clipped with an electric clipper or even scissors rather than shaved. The patient should be instructed not to shave the operative site before surgery because it has been shown to increase the risk of wound infection and cellulitis.

TOTAL ABDOMINAL HYSTERECTOMY: SURGICAL TECHNIQUE

Previous editions of Te Linde's text have described gradually evolving modifications of Edward H. Richardson's technique for abdominal hysterectomy with which thousands of gynecologic surgeons have been trained over the years. The operative technique was first published in 1929, and because Te Linde felt it was a classic, he quoted it word for word in the fourth edition of this textbook with two added "modifications." This was the edition on my bedside table when I was a resident. I have had the good fortune to operate with many fine surgeons, including E. Stewart Taylor and Felix Rutledge, and have been challenged by many young residents over the years. These experiences have been further enhanced by discussions of surgical technique with gynecologists from around the world, who have suggested changes or ideas that I have tried and sometimes incorporated into my basic technique for abdominal hysterectomy. Although it is important

P.703

to learn a basic technique for standard abdominal hysterectomy, every surgeon should be interested in observing new and different techniques or modifications to be tried from time to time when appropriate. As a resident, you should try all of the different techniques used by the different attending physicians, always asking why this clamp is used or that suture or needle is selected or why the cuff is left open or closed. Having tried many different ideas, each gynecologic surgeon gradually evolves her or his own basic techniques that feel comfortable, work for him or her, and make sense. Because each patient is unique, it also is useful to have experience with different techniques and various modifications of the basic operation so that when the occasion calls for it, an alternative technique that is more suitable for the particular situation can be employed. Our basic

technique for abdominal hysterectomy and several modifications are described in the following.

On the day of surgery, the surgeon always attempts to see the patient and her family and supporters before she is brought into the operating room. Although surgery may be routine to the gynecologist, major surgery is often a once-in-a-lifetime, frightening experience for the patient. The calm reassurance of the surgeon and the professional and caring nature of the entire operative team are very helpful to the patient and her family at this point. The focus of attention should be on the patient and her surgery. A certain amount of relaxed chatter about someone's birthday or hospital gossip is reasonable, but the patient should feel that the concentration of the surgical team is focused on the surgery at hand. Remarks about other patients or how the surgeon had to stay up all night with a difficult patient in labor are not appropriate. An equipment problem or technical difficulties that affect the operation certainly should be discussed with the surgeon before starting the procedure; however, it is inappropriate to talk about these in front of the patient. Remarks such as "The table is broken and won't go down" or "We weren't able to get your favorite retractor today" may not affect the performance of the operation, but such statements just before a patient is ready to be anesthetized may raise serious doubts as to whether the operative team is optimally prepared for this operation and may raise uncomfortable questions later if complications or unexpected results occur.

Positioning

The patient is brought into the operating room and placed in the supine position on the operating table. It is nice to place a warm blanket on the bed immediately before the patient's arrival and to cover the patient with a blanket from the warmer or use a warm air circulating blanket when she is positioned on the operating table because most operating rooms are somewhat cool and the patient is only lightly clothed.

When the patient has been anesthetized, a careful examination under anesthesia is done. At this point, the surgeon should concentrate on potential problems affecting resectability. Is there nodularity from endometriosis in the cul-de-sac that may make dissection of the rectum off of the posterior cervix difficult? Is the myoma in the broad ligament really wedged into the pelvic sidewall or does it move freely with the uterus? The mobility and descent of the uterus under anesthesia are particularly important when a vaginal hysterectomy is being considered. These potential problems and possible solutions should be considered and possibly discussed with the operative team while the surgeon scrubs. By consideration and discussion of potential problems and possible solutions, difficulties that arise during surgery may have already been contemplated and plans and solutions already developed.

The vagina and perineum are prepped with antiseptic solutions, and a Foley catheter is inserted. I prefer to position the patient supine on the operative table with a soft pillow under her knees to provide gentle flexion. The patient's legs provide a table on which instruments can be placed. These days, it is common for the patient to be positioned in the low Allen stirrups with her legs slightly apart. This allows an assistant to stand between the legs and provides ready access to the vagina for examination or manipulation and the urethra for cystoscopy, which is routine in most pelvic surgery.

The abdomen then is prepped from the anterior thighs to the xiphoid, and sterile drapes are applied. In most instances, abdominal hysterectomy for benign disease can be done through a low transverse incision; most gynecologists prefer a Pfannenstiel incision, which is cosmetically appealing and strong. If more exposure is required, a Cherney or Maylard incision can be used. A midline incision is usually done if malignant disease is present or exposure to the upper abdomen may be required. The choice of abdominal incision is discussed in [Chapter 14](#).

Once the abdomen is opened, the pelvic pathology is carefully evaluated and the abdomen explored. The operating surgeon should examine the appendix and palpate the upper abdominal organs, including the kidneys, liver, gallbladder, stomach, spleen, diaphragm, bowel, and omentum. The retroperitoneal nodes in the pelvic and

paraortic area should be palpated and the area of the pancreas gently examined to identify any abnormalities. The status of these organs should be recorded in the operative note, and an intraoperative consultation may be indicated if abnormalities are identified.

After the abdomen has been explored, a slight Trendelenburg position should be requested, a self-retaining retractor placed, and the bowel packed superiorly to afford good exposure of the pelvis. Any adhesions of the small bowel or rectosigmoid may need to be divided at this time so that the bowel can be mobilized out of the operative field. In relatively thin patients with benign disease, I prefer to use a Kirschner retractor, which is light and simple and provides a choice of several fairly wide, shallow blades that fit on a square frame, allowing adjustable retraction laterally, inferiorly, and superiorly. The cecum and sigmoid are packed first with separate packs, and a third rolled or folded pack is placed in the center behind the superior retractor blade to hold back the small bowel. In larger patients, or patients with a longer midline incision, a Bookwalter or Omni-Tract retractor, with many options of blades and variable positioning, is invaluable. These large retractor systems are screwed onto the operating table and provide excellent retraction in almost any situation. They are particularly useful in obese patients.

Hysterectomy

When the bowel has been packed away and exposure to the pelvis is satisfactory, the round ligaments and uteroovarian ligaments are grasped on each side with a Kocher clamp, elevating the uterus out of the pelvis. In some cases of extensive inflammatory disease, endometriosis, malignancy, or very large fibroids, uterine mobility is limited; but in most benign conditions, uterine mobility is satisfactory. The operator is generally on the patient's left side so that the right-handed surgeon can use her or his dominant hand to extend down into the pelvis. The first assistant is on the opposite side. The uterus is retracted to the patient's left side, and the right round ligament is stretched taut. A 0 delayed absorbable suture is placed under the round ligament approximately halfway

P.704

between the uterus and the pelvic sidewall. The small artery of Sampson runs just under the round ligament and, in many cases, transilluminating this area allows the surgeon to easily visualize the artery and be sure that the suture is passed under it so that the artery will be ligated. A second suture is placed approximately 1 cm medial to the first suture; these two sutures are now tied simultaneously by the surgeon and first assistant. Clamping the round ligament is an extra step that is rarely necessary.

With traction on these sutures, the round ligament is held taut and divided with Metzenbaum scissors between the two suture ligatures (**Fig. 32A.1**). This opens the retroperitoneal space, which is almost always a free space for blunt dissection, even in the patient with extensive tumor, inflammatory disease, or endometriosis. *If the ovaries are to be removed at the time of hysterectomy*, the peritoneal incision then is extended superiorly, lateral to the ovary and parallel with the infundibulopelvic ligament. The peritoneal incision also can be extended anteriorly down to the bladder reflection, but the peritoneum over the anterior cervix does not need to be divided at this time because exposure of this area is not yet required and bleeding may be encountered. With the index finger and the tip of the suction or the back of a tissue forceps, the surgeon gently divides the loose areolar tissue of the retroperitoneum, identifying the external iliac artery on the medial surface of the psoas muscle. In most cases, the artery can be identified very easily, and blunt dissection is used to extend the exposure superiorly to the level of the bifurcation of the common iliac artery. The ureter always crosses the pelvic brim at this location and should be identified easily on the inside of the medial leaf of the peritoneum at this point. The internal iliac or hypogastric artery dives into the pelvis at this location parallel to the ureter, and it should be identified also. This retroperitoneal exploration may seem awkward at first, but with practice, the external and internal iliac arteries and ureter can be visualized easily in 10 to 20 seconds.

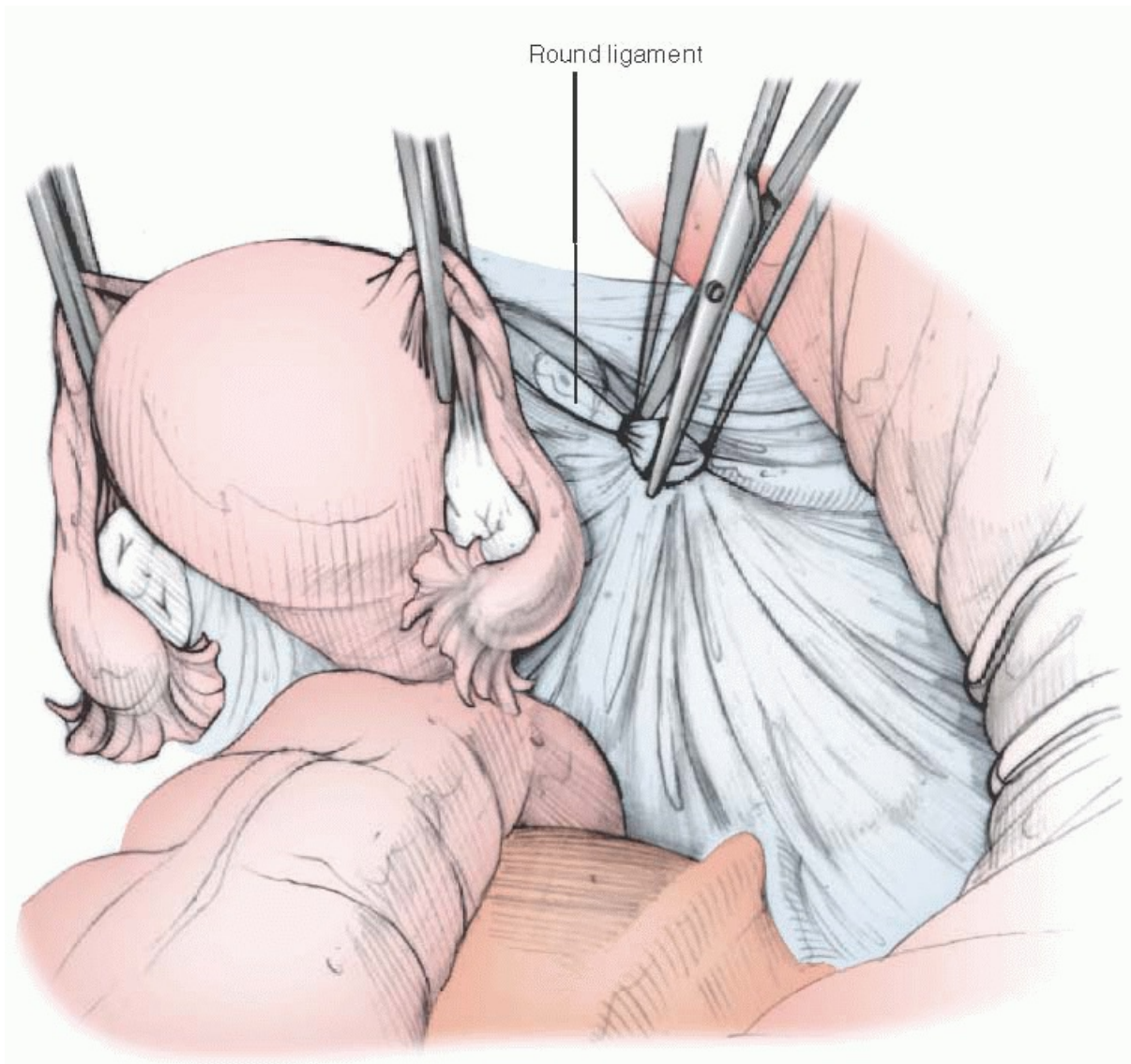


FIGURE 32A.1 The technique of abdominal hysterectomy begins with the round ligament. The ligament is ligated with transfixion sutures and cut. The broad ligament is opened.

If the ovary is to be removed, a hole in the peritoneum between the ureter and the ovarian vessels superior to the ovary can be made under direct vision. We use a fairly fine sharp-pointed 9-inch clamp that can be passed gently through the peritoneum from lateral to medial against and between two fingers, supporting the medial side of the peritoneum. Alternatively, the peritoneum may be divided sharply or with the electro-surgical blade. We prefer to use a fairly delicate tonsil clamp on the infundibulopelvic ligament because it reminds us to isolate the vessels and take a fairly small pedicle. If there is significant inflammation or edema, a larger clamp, such as a Heaney clamp, may be used on the infundibulopelvic ligament pedicle ([Fig. 32A.2](#)). A second back clamp then is placed distally and the ovarian vessels divided between the two clamps. This pedicle then is ligated with a free tie, and then, a second transfixion suture ligature is placed for safety between the free tie and the clamp. Zero-gauge delayed absorbable sutures and ties are used throughout. The suture ligature is placed distal to the free tie so that if the needle happens to puncture one of the ovarian vessels, the vessel has already been ligated by the more proximal free tie. The back clamp is ligated with a single free tie, and the posterior peritoneum then is torn or cut above the ureter toward the back of the uterus, mobilizing the ovary, which is then tied to the clamp on the right side of the uterus to keep it from flopping around and obscuring the operative field. The sutures on the round ligaments and infundibulopelvic

ligament then are cut. The procedure is repeated on the patient's left side.

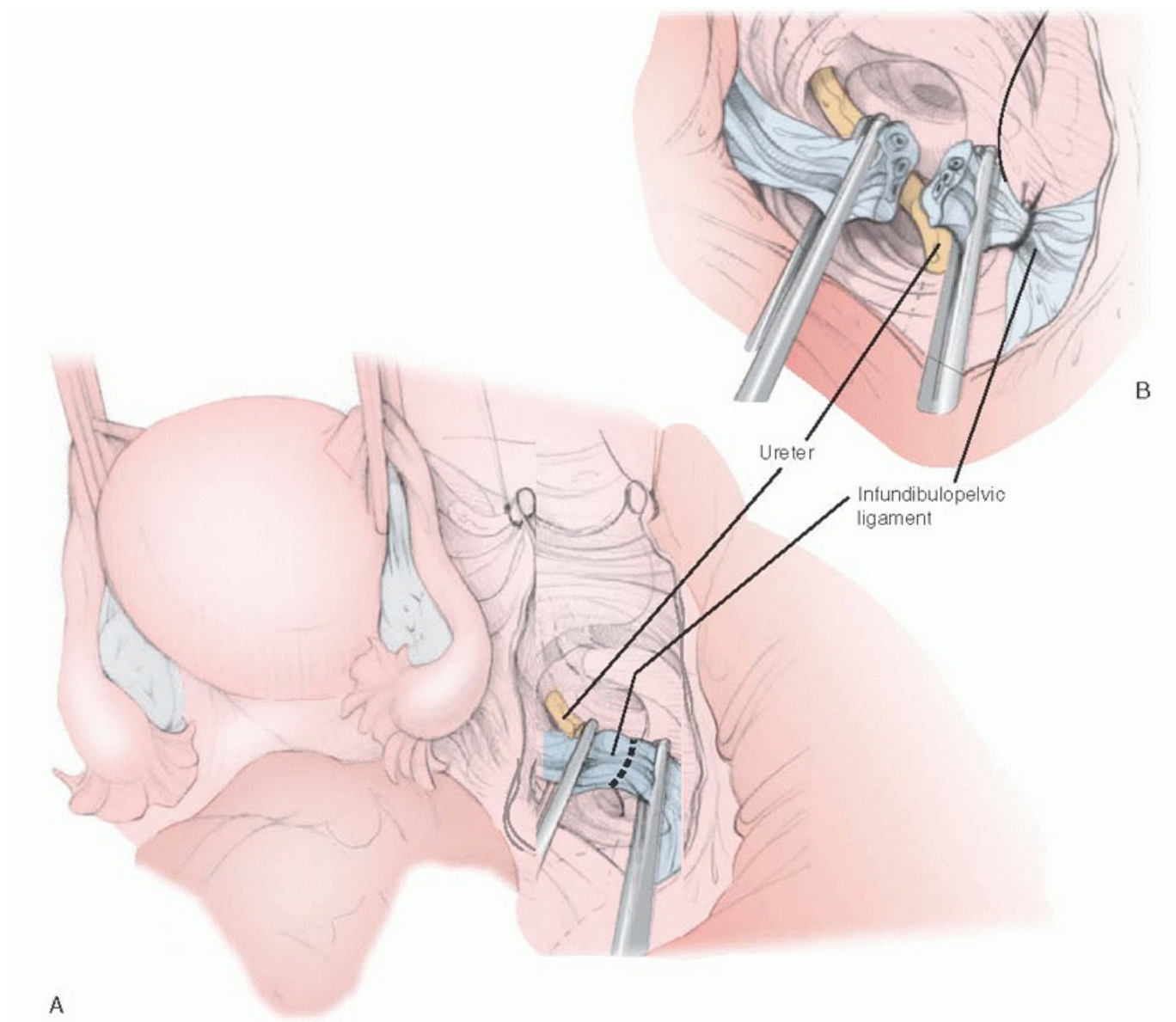


FIGURE 32A.2 A: The infundibulopelvic ligament is doubly clamped, and the ovarian vessels are cut between the clamps. Care is taken to be sure the ureter is clear as the clamps are applied. **B:** The proximal pedicle is ligated with a free tie followed by a transfixion suture ligature.

If the ovary and tube are to be left in situ at the time of hysterectomy, a window in the peritoneum beneath the fallopian tube between the uterus and ovary is made sharply or bluntly, and a heavy clamp—such as a Heaney, Kocher, or similar clamp—is used to clamp the uteroovarian pedicle (Fig. 32A.3). The round ligament should not be included in this clamp. The clamp that was initially placed on the round ligament and fallopian tube just lateral to the uterine fundus at the beginning of the procedure serves as the back clamp for this pedicle. The tube and uteroovarian ligament are divided and the pedicle ligated as previously noted with a free tie followed by a suture ligature. The ovary and tube may be left in the posterior pelvis if exposure is adequate or gently packed in the paracolic gutter, with care being taken to ensure that the blood supply is not compromised.

The next step is the dissection of the bladder from the anterior cervix. With the uterus elevated out of the pelvis by traction on the clamps on the tube and round ligament, the bladder peritoneum is divided just inferior to its attachment to the lower uterine segment. If the peritoneum is divided 5 to 10 mm below its uterine attachment, it is usually mobile, and an avascular plane of loose areolar tissue can be identified between the posterior bladder wall and the anterior cervix. We begin this dissection sharply using the Metzenbaum scissors. With upward traction on the bladder peritoneum and the uterine fundus stretched tightly out of the pelvis, the tips of the Metzenbaum scissors should rest lightly on the fascia overlying the cervix and small bites used to develop this

tissue plane, dissecting the bladder from the anterior cervix (**Fig. 32A.4**). This dissection should take place over the cervix, because if it is carried too far laterally, bleeding may be encountered, and the uterine vessels or ureters could be injured. Except in patients with a previous cesarean section or an adherent bladder for other reasons, this bladder dissection often can be done bluntly, but it is good practice to do it sharply from time to time so that in those patients in whom the bladder is adherent and sharp dissection is required, the technique will be familiar. Blunt dissection of the bladder can be accomplished easily by

P.706

grasping the uterus and lower uterine segment between both hands and gently using the first one or two fingers to advance the bladder, as illustrated in Richardson's classic paper (**Fig. 32A.5**). It also is possible to grasp the uterus with your dominant hand, placing the thumb in front on the anterior cervix and the fingers behind the uterus. The thumb is gently pushed downward toward the cervix and inferiorly toward the vagina, gently dissecting the bladder off of the cervix and lower uterine segment. With this technique, the pressure is against the cervix rather than against the bladder, which should minimize

P.707

the risk of bladder injury. Excessive force should not be used. As the bladder is dissected below the cervix, the thumb in front and the fingers behind come into closer opposition because they now have only the vaginal wall between them. The dissection is extended laterally to encompass the full cervix. Usually, it is not necessary to dissect the rectum off of the posterior culde-sac; but if adherent rectum prevents good posterior exposure, it should be dissected free after the uterine vessels have been divided.

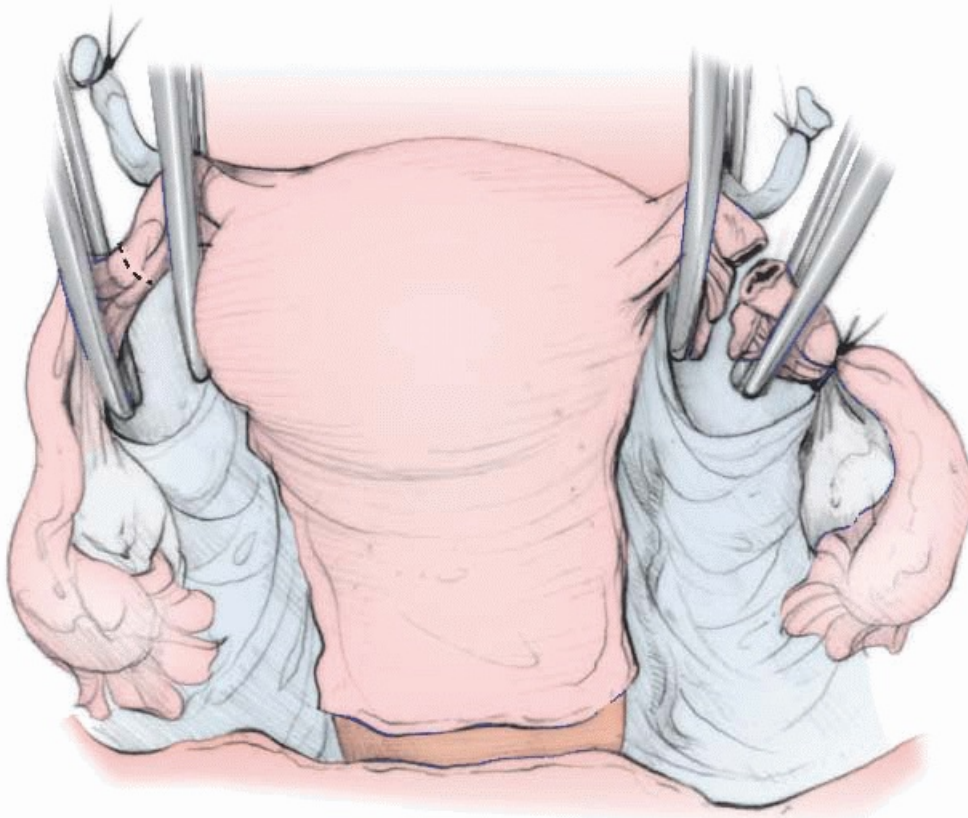


FIGURE 32A.3 When the ovary is to be conserved, a peritoneal window is made above the ureter and the tube and utero-ovarian ligament are clamped. This pedicle is divided and doubly ligated.

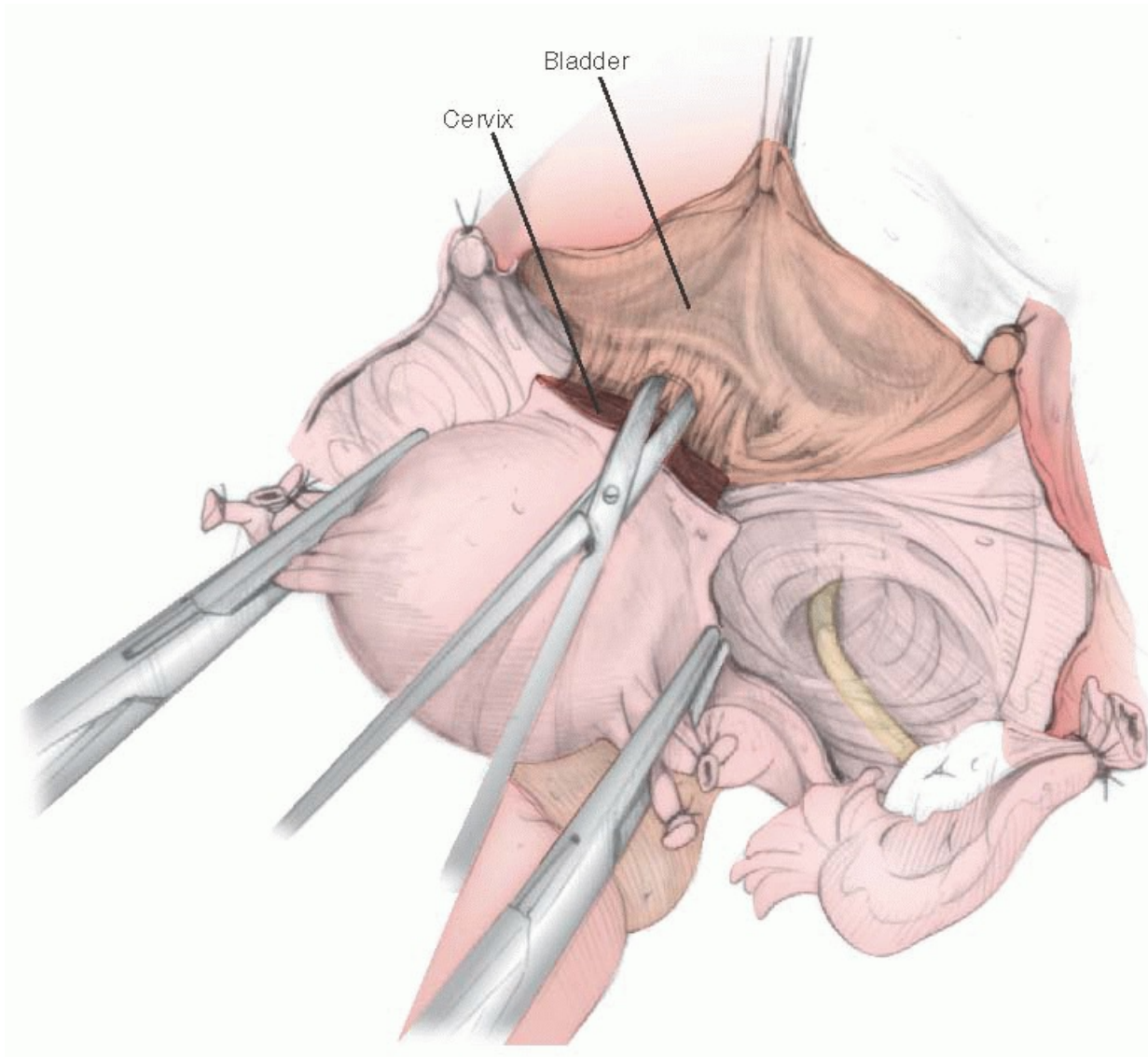


FIGURE 32A.4 The bladder is mobilized inferiorly by sharp dissection away from the cervix. To avoid unnecessary bleeding, this step may be done in stages as necessary.

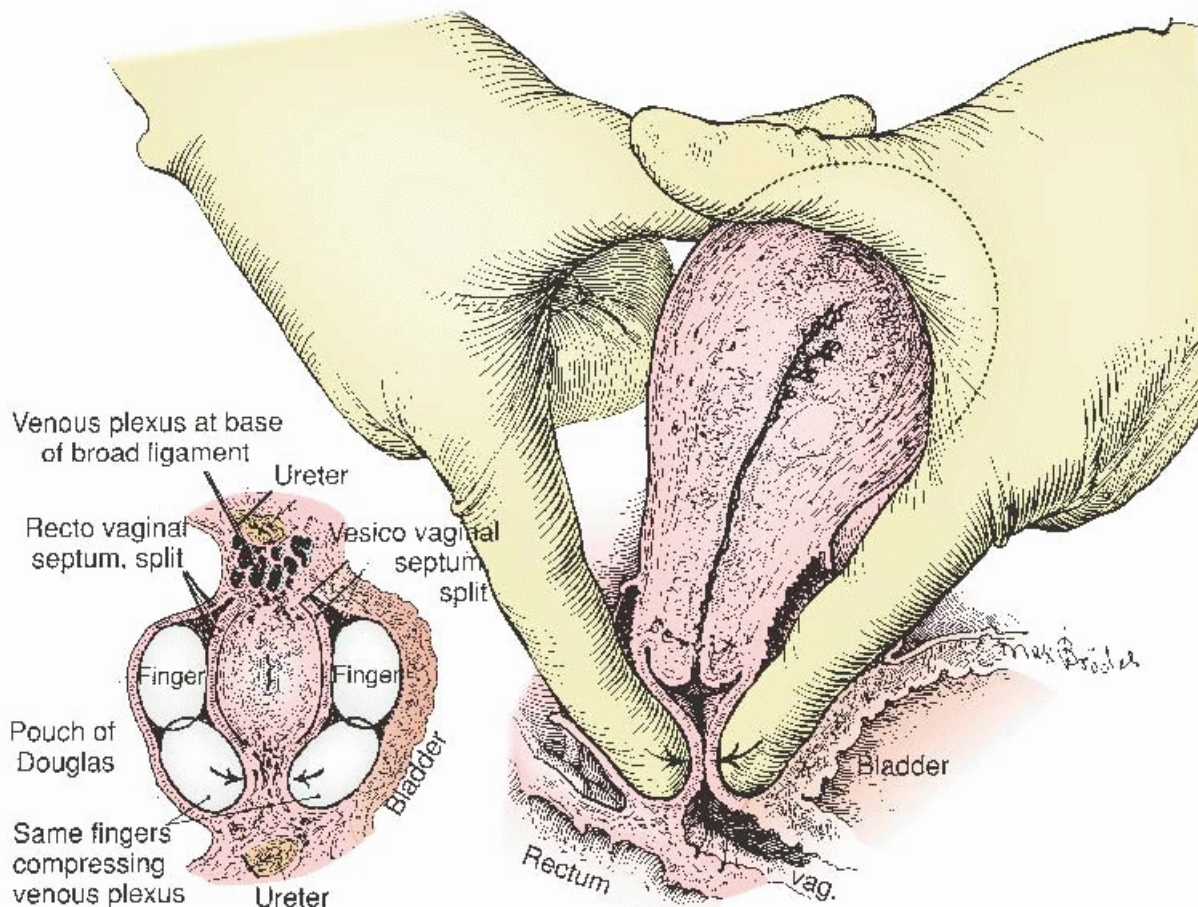


FIGURE 32A.5 The bladder and, if necessary, the rectum can be gently advanced with blunt dissection. The depth of this dissection can be checked by squeezing the anterior and posterior fingers together below the cervix. (From Richardson EH. A simplified technique for abdominal panhysterectomy. *Surg Gynecol Obstet* 1929;48:248, with permission.)

Once the bladder has been freed from the anterior cervix, the uterine artery and vein are skeletonized (**Fig. 32A.6A**). The uterus is pulled sharply to the patient's left side, and the surgeon gently dissects the loose fatty tissue adjacent to the lateral lower uterine segment on the right. The uterine artery is usually found immediately adjacent to the uterus at the level of the internal cervical os. In most patients, the uterine artery is easily exposed by holding the tissue laterally and gently "raking" with the Metzenbaum scissors slightly opened from medial to lateral. "Skeletonizing" the uterine artery and vein allows them to be clamped more accurately, with less adjacent tissue, and a smaller vascular pedicle, which allows more precise and more secure ligation. However, good surgical judgment should be used so that excessive attempts to isolate the vessels do not produce unnecessary bleeding. When the vessels are exposed, a fairly heavy, slightly curved clamp then is used to clamp the vessels just adjacent to the uterus (**Fig. 32A.6B**). We prefer to use a Heaney, Zeppelin, or Masterson clamp for these pedicles. The tip of the clamp should be around the vessels, and the clamp should come across the pedicle as close to a right angle as possible, rather than at the diagonal, so that the least amount of tissue will be incorporated in the pedicle. The tip of the clamp should not include too much cervical or uterine tissue because this makes application of subsequent clamps more difficult. A second clamp can be placed above the first for added safety, if desired, and a third or back clamp used to prevent annoying back bleeding from the uterus after the vessels have been cut if the uterus is enlarged or the other vascular pedicles to the uterus have not been secured.

If exposure is satisfactory after a single clamp has been placed on the right uterine artery and vein, we skeletonize the uterine vessels on the patient's left side and place a clamp on these vessels as well. If the uterus

is small, no back clamp is required because the four major vessels supplying the uterus have now been clamped or ligated. Next, the uterine vessels are cut with scissors or a knife and the pedicle doubly ligated with 0 delayed absorbed sutures. We prefer to use a small tapered point needle (CT-2, Ethicon) for these pedicles because we feel that large needles are more difficult to place in the small confines of the deep pelvis. If a back clamp has been used, it is now ligated and removed so that the field is not obscured by an excessive number of clamps. The technique illustrated here starts with the right side, but the patient's anatomy and surgical preference should guide which side is skeletonized and clamped first.

Hemostasis should be good at this point. If not, any bleeding should be controlled. The bladder is again checked to ensure it is well below the cervix. If the rectum needs to be dissected from the posterior cervix, this should be done now. This is usually not necessary for a simple abdominal hysterectomy for benign disease. The peritoneum of the posterior cul-de-sac between the uterosacral ligaments can be divided easily, and blunt dissection of the posterior vaginal wall from the anterior rectum usually is easy, although the rectosigmoid occasionally may be densely adherent to the posterior uterine segment or cervix by endometriosis or pelvic inflammatory disease. If the bladder and/or rectum is too densely adherent and there is concern that further attempts at dissection may damage them or cause troublesome bleeding, a supracervical hysterectomy should be considered.

Once the bladder has been freed from the cervix anteriorly and the rectum posteriorly, the uterus is placed on tension, exposing the deeper portions of the broad ligament and

P.708

pulling the lower uterine segment away from the ureter. A medium-width malleable retractor may be useful to retract the bladder anteriorly; if necessary, a wide malleable retractor in the posterior cul-de-sac will provide deep exposure posteriorly. In most cases, a series of straight Heaney or Zeppelin clamps can now be used to successfully clamp the remaining portion of the broad ligament ([Fig. 32A.7](#)). The tips of these clamps should be placed on the lateral portion of the cervix, and the upper portion of the jaw should lie immediately adjacent to the previous pedicle. As the clamp is gently squeezed closed, the tip slides off of the firm cervix, finally closing snugly against the lateral wall of the muscular cervix. By staying close to the cervix in this way, the risk of damaging the ureter, which is not too far away laterally, is minimized. The pedicle then is cut with heavy scissors or a knife. A millimeter or two of tissue may be left medial to the clamp as insurance, but this is not necessary. The tip of the transfixion suture needle is placed at the lateral tip of the clamp jaw; if the pedicle is longer than 1 cm, we recommend using a Heaney suture ligature so that the upper end of the pedicle is secondarily transfixed to prevent it from slipping out of the ligature. While good exposure is maintained, one or two pedicles are tied on each side, and then the procedure is repeated on the opposite side until the level of the cervical-vaginal junction has been reached. Once again, the bladder and rectum are checked and advanced if necessary to be sure that they are well clear and the anterior and posterior vaginal walls exposed.

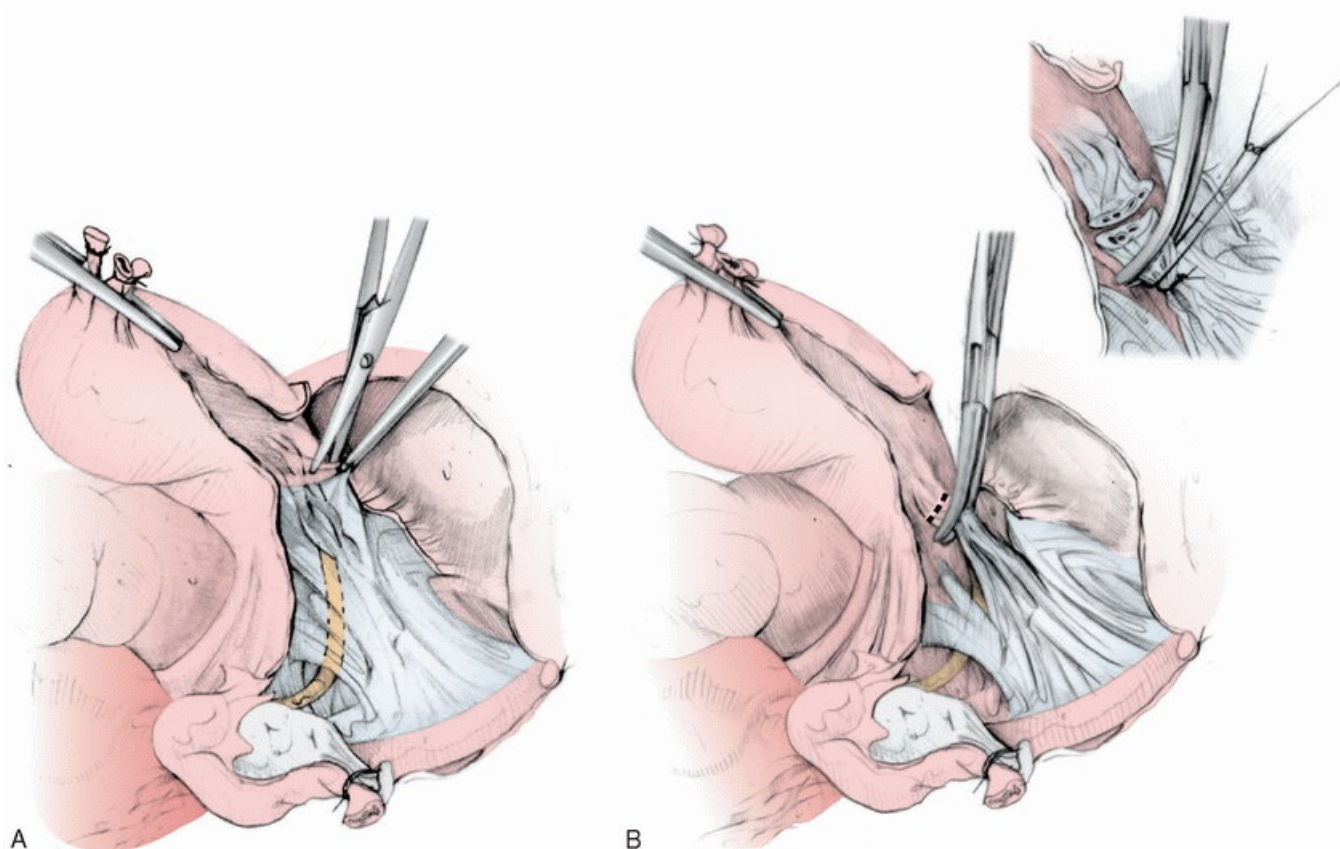


FIGURE 32A.6 A: The uterine vessels are skeletonized. **B:** A curved Heaney clamp is used to clamp the uterine vessels immediately adjacent to the uterus. They are ligated by two suture ligatures.

Sharply angled large Zeppelin clamps are used to clamp across the vagina below the cervix. These clamps include the base of the cardinal ligaments laterally, the uterosacral ligament posteriorly, and the vaginal wall anteriorly and posteriorly. A clamp is applied from each side; in most cases, the

P.709

tips of these clamps meet in the middle just below the cervix (**Fig. 32A.8**). A knife or heavy, sharply angled Jorgenson scissors is used to divide the vagina above these clamps and below the cervix. The uterus is removed and placed in a pan on the back table for later examination. Care is taken not to contaminate the surgical field by touching the vagina or vaginal portion of the cervix or dripping vaginal fluid in the pelvis. A single figure-of-eight suture is placed between the tips of the two clamps to close the midportion of the vagina. The ends of this suture are held initially and not tied. A Heaney suture ligature is placed on each of the lateral clamps with the second bite going through the uterosacral ligament posteriorly. Inclusion of the uterosacral and cardinal ligament in this pedicle provides excellent support of the vaginal apex. When these lateral sutures have been tied, the figure-of-eight suture in the middle then is tied also. The lateral sutures are cut and the figure-of-eight in the middle of the cuff is held to provide traction on the vaginal apex. With this closed cuff technique, the vagina is never exposed, which reduces contamination of the pelvis. However, there may be instances, such as a large cervical myoma, when there is a very deep vaginal fornix, and a closed technique would remove too much vagina. Entry into the vagina with the electrosurgical blade and then carefully opening the vagina circumferentially under direct vision is an option in such cases. As the vagina is opened, the full-thickness vaginal edges are grasped with Kocher clamps as the dissection proceeds. In this instance, we generally close the vaginal cuff with a series of figure-of-eight stitches of 0 delayed absorbable suture, taking care to incorporate the uterosacral and cardinal ligaments into the cuff for support. Since the advent of prophylactic antibiotics for hysterectomy many years ago, we have not run the vaginal wall with a locking stitch for hemostasis and left the cuff open for drainage (closing the pelvic peritoneum over the open cuff).

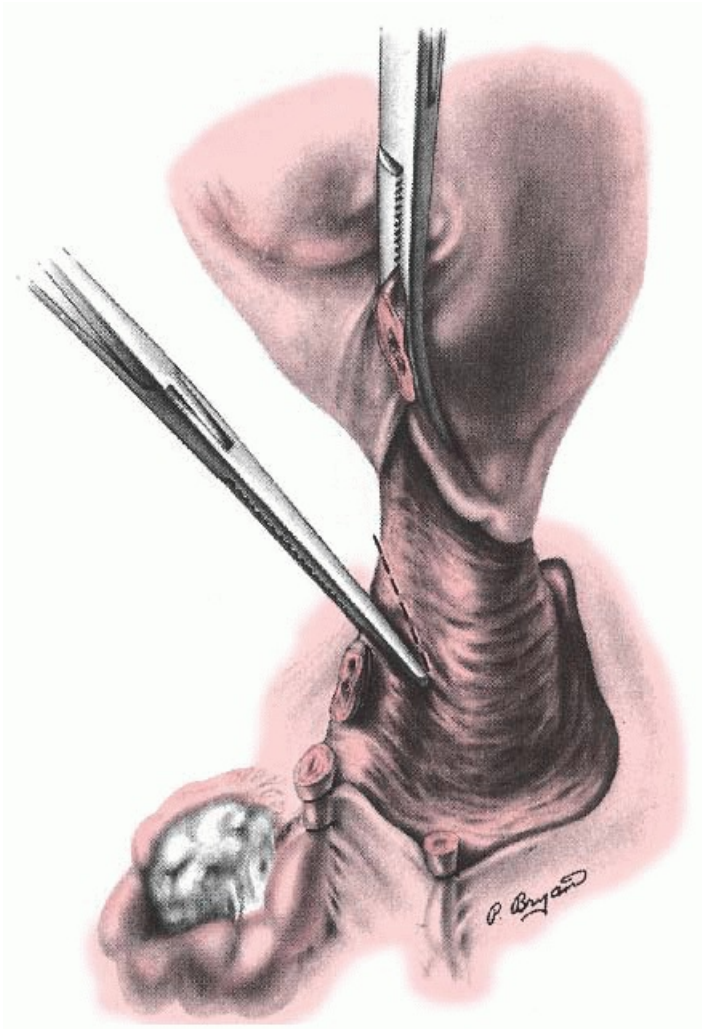


FIGURE 32A.7 After the uterine artery and vein have been ligated, the remaining lower portion of the broad ligament is clamped with a series of straight clamps. The tips are placed on the edge of the cervix and the back of the jaw immediately adjacent to the previous pedicle.

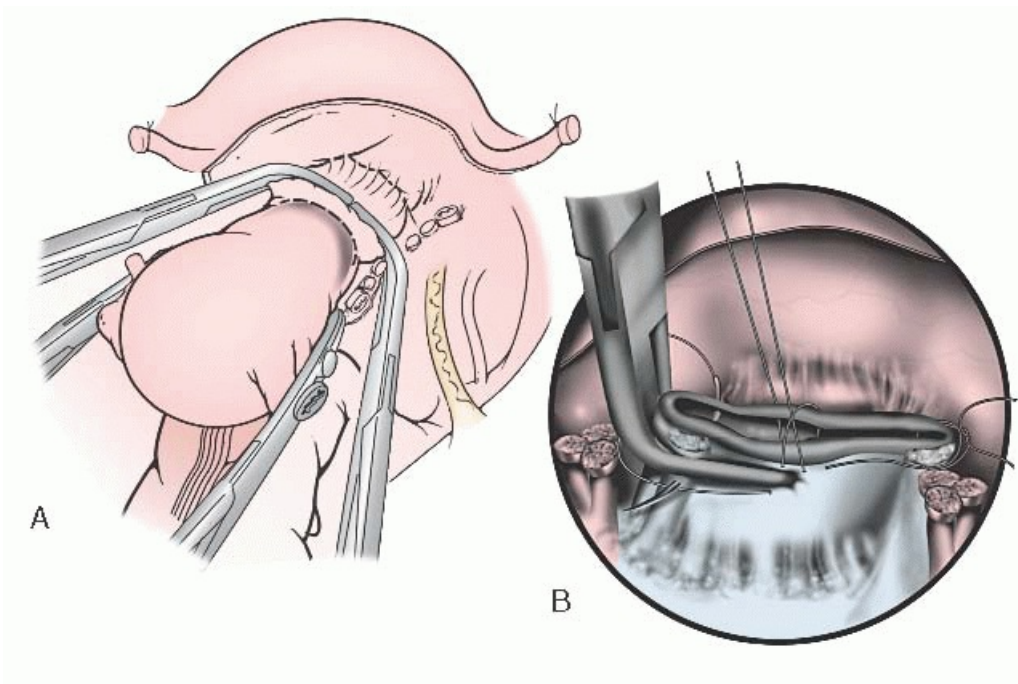


FIGURE 32A.8 A: After checking to be sure the bladder and rectum are clear, the vagina is cross clamped with long, sharply curved Zeppelin clamps just below the cervix (*dotted line*). The vagina is divided just above the

clamps with a knife or angled scissors. **B:** The vaginal cuff then is closed with a figure-of-eight suture in the middle and Heaney suture ligatures on the angles, including the uterosacral and cardinal ligaments for support.

In the classic Richardson technique, the peritoneum over the posterior cervix is divided, the peritoneum is dissected off the cul-de-sac, and the rectovaginal septum is entered to reflect the rectum posteriorly. In our experience, this has not been necessary in the vast majority of patients with benign disease. In contrast to the anterior bladder dissection, this posterior peritoneum is much more adherent. There is usually some bleeding associated with this dissection, making it both bloody and time-consuming. With the Richardson technique, the uterosacral ligaments also are clamped separately and subsequently attached to the vaginal cuff for support. In the technique described above, this is accomplished in a single step.

STEPS IN THE PROCEDURE

Abdominal Hysterectomy

1. Open the abdomen and visualize and/or palpate the pelvis, abdomen, and retroperitoneal area to evaluate the presence of normal or abnormal findings and anatomy.
2. Place a retractor if needed to provide adequate exposure for safe pelvic surgery.
3. Grasp the round ligament, utero-ovarian ligament, and fallopian tube with a large bite of a straight clamp (Kocher) where they arise from each side of the uterus. One clamp on each side will provide an easy way to manipulate the uterus.
4. Elevating the uterus out of the pelvis, the anatomy is reevaluated and any adhesions to adjacent bowel or omentum are freed.
5. The round ligament on one side is ligated and divided, opening the retroperitoneal space.
6. If the ovaries are to be preserved, the utero-ovarian pedicle is clamped, divided, and ligated.
7. If the ovary is to be removed, the retroperitoneal space is opened, the ureter is identified, and the infundibulopelvic ligament (containing the ovarian artery and vein) is isolated, clamped, divided, and ligated.
8. Steps 5, 6, and 7 are then repeated on the opposite side.
9. The bladder is then dissected free from the anterior wall of the lower uterine segment and cervix so that the anterior vaginal wall is exposed.
10. The uterine vessels are skeletonized on both sides at the level of the lower uterine segment.
11. The uterine vessels are clamped bilaterally. The uterine vessels are then divided and suture ligated (usually with two sutures on each side).
12. The exposure of the anterior and posterior vaginal wall just below the cervix is again checked, and the bladder and rectum are dissected still more if additional exposure is needed to safely clamp across the vagina below the cervix.
13. The remaining portion of the broad ligament on each side of the cervix is then clamped, divided, and ligated using a series of clamps until the cervix is reached, and the broad ligament on each side has been detached from the lateral cervix and upper vagina is well exposed.
14. With the uterus strongly elevated out of the pelvis, large right angle clamps are placed across the vagina just below the cervix—one from each side with the tips meeting the middle.
15. The vagina is divided with a knife or long heavy curved scissors above the clamps, and the uterus and cervix are passed off the operative field.
16. The vaginal apex is closed. Heaney suture ligatures can be used on each side incorporating the uterosacral and cardinal ligaments into the cuff for support.
17. The pelvis is irrigated with warm, sterile saline and hemostasis is checked. The packs and retractors are removed, and the sigmoid colon is carefully replaced in the pelvis.

Closure

After the pelvis has been copiously irrigated with warm saline, the pedicles are inspected carefully to be sure that hemostasis is present. Electrocautery or suture ligatures with 3-0 absorbable sutures on fine needles are used to control small bleeders. The location of the ureters, bladder, and major vessels should be known when placing these sutures. Common sites of ureteral injury during abdominal hysterectomy include the infundibulopelvic ligament where the ovarian vessels are ligated, the area of the uterine artery ligation, and the bladder base. Distorted anatomy associated with fibroids, endometriosis, and malignancy is a signal for special care to avoid ureteral injury. The pelvis is not reoperitonealized, but the rectosigmoid colon is gently laid over the vaginal cuff to cover this raw surface and minimize the risk of small bowel adhesions. The packs and retractor are removed, the abdomen checked again for hemostasis, and the omentum placed anteriorly to minimize the risk of intestinal adhesions to the abdominal incision. The anterior peritoneum is closed with delayed absorbable suture, although some surgeons today feel that it is unnecessary to close the abdominal peritoneum. The fascial closure should be commensurate with the patient's risk of infection and hernia. Generally, a running monofilament delayed absorbable suture such as PDS (Ethicon) on a larger, curved, tapered needle (CT-1, Ethicon) can be used. If there is a significant risk of dehiscence secondary to infection, obesity, or other medical problems, interrupted sutures or a mass closure technique may be used. Closure techniques are illustrated in [Chapter 14](#). Because patients are often discharged by the third or fourth postoperative day, we generally prefer to close the skin with a subcuticular absorbable suture, which eliminates the necessity for a return to the office for suture or staple removal.

After the patient has been taken to the recovery room, the surgeon should speak with the family, preferably face to face, to assure them that the patient is doing well and to review the operative findings with them. We also strongly recommend that the surgeon ask the circulating nurse to contact the family about once an hour to update them on the progress of the operation during the surgical procedure. This especially is helpful if there were any unknown questions going into the operation (Did the ovaries look normal? Was the endometriosis involving the ureter?). A brief operative note must be immediately recorded in the patient's chart describing the procedure, blood loss, fluid replacement, and if any packs or drains were left in the patient. Postoperative orders are written. A full and complete operative note should be prepared with emphasis on any unusual findings or variations from standard techniques.

SUBTOTAL ABDOMINAL HYSTERECTOMY

The technique of subtotal or supracervical abdominal hysterectomy is similar to the technique for abdominal hysterectomy as described, until the uterine vessels have been clamped and ligated. At this point, care should be taken to be sure that the bladder and rectum have been advanced at least far enough so that the cervix can be clearly visualized both anteriorly and posteriorly. The uterine fundus is strongly retracted out of the pelvis, and electrocautery is used to cut the cervix anteriorly just above the level of the ligated uterine vessels ([Fig. 32A.9](#)). A shallow V-shaped incision is used both anteriorly and posteriorly until the uterine fundus is excised. The "coagulate" mode of the electrosurgical unit is used, and hemostasis usually is excellent. An attempt to cut across the upper cervix should not be made until the uterine vessels have been ligated bilaterally. Bleeding will be prohibitive. Once the fundus has been amputated, several generous figure-of-eight sutures on a large needle then are used to close the upper endocervix in a hemostatic fashion. The top of the cervix is checked for bleeding, and the bladder peritoneum may be used to cover this cervical stump to minimize the risk of adhesions.

POSTOPERATIVE CARE

Although routine postoperative care is thoroughly reviewed in [Chapter 9](#), there are several facets that should be emphasized following hysterectomy.

Studies over the past few years have indicated that early feeding after hysterectomy is safe and actually results in earlier discharge. In many cases, patients are able to tolerate solid food on the first postoperative day following abdominal hysterectomy. The surgeon should nevertheless take into account the amount of dissection and bowel trauma that occurred during the operative procedure and be conservative with the diet orders if a postoperative ileus is anticipated. Patients and their caregivers always should be cautioned not to eat or drink if they feel nauseous or are vomiting. Having a bowel movement or even the passage of flatus are no longer requirements for hospital discharge as long as the patient has normal, active bowel sounds, is tolerating solid food, and is not distended.

P.711

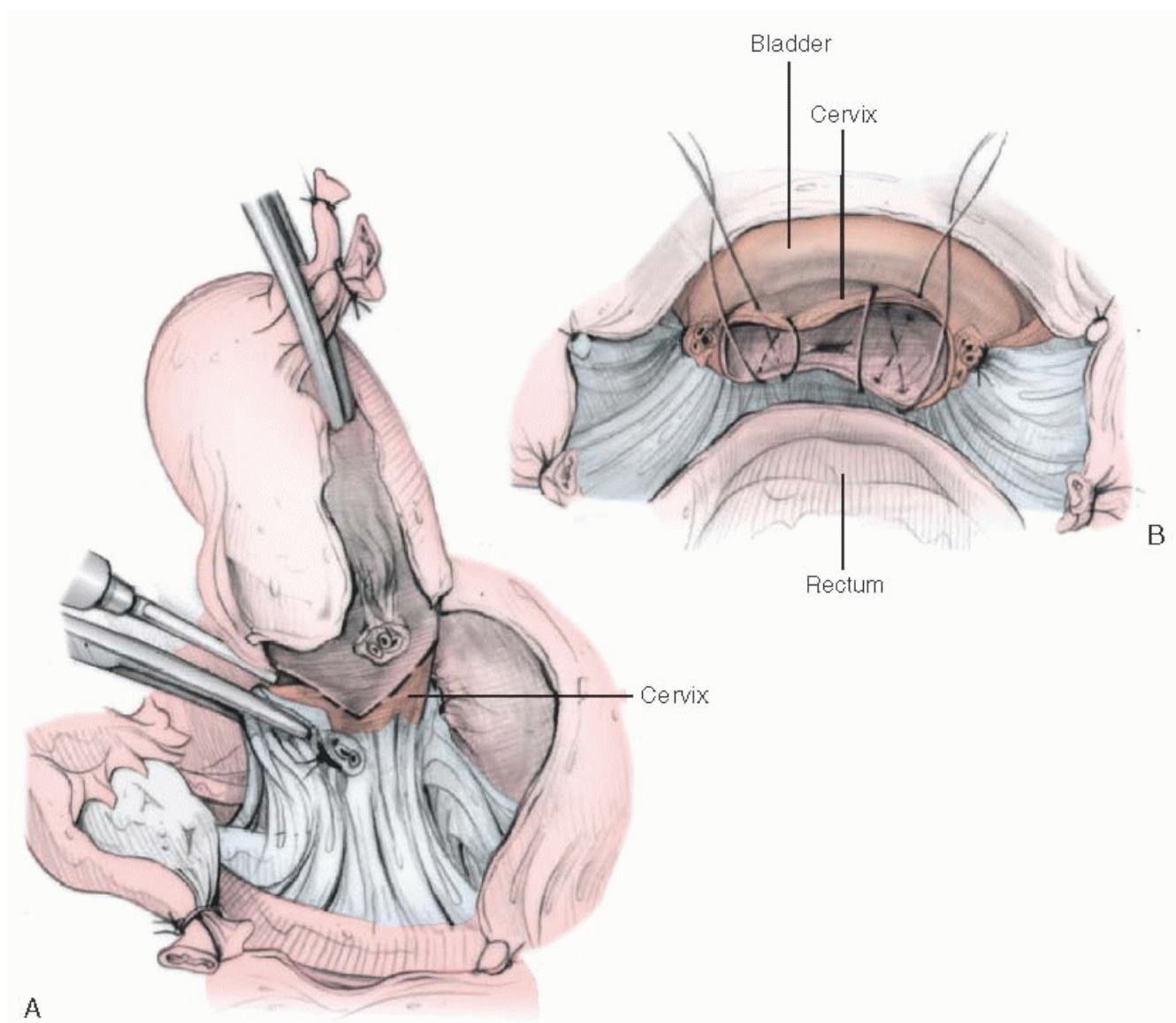


FIGURE 32A.9 Subtotal or supracervical hysterectomy. **A:** After the uterine vessels have been ligated, the fundus is amputated using the electrocautery in a shallow cone-shaped technique. **B:** The cervix or lower uterine segment then is closed with several large figure-of-eight sutures.

Most patients have a Foley catheter for bladder drainage overnight following abdominal hysterectomy, although Richardson and many gynecologic surgeons have shown it is possible to avoid this in many patients with the help of a good, enthusiastic nursing staff. In most situations, however, a catheter is inserted before hysterectomy

and removed on the first postoperative day. In patients with bladder injury or continuous epidural for postoperative pain relief, more prolonged catheter drainage may be indicated.

The length of postoperative hospitalization has decreased dramatically in the last 20 years. Although it was common in the past for women to remain in the hospital for 7 to 10 days after abdominal hysterectomy, most patients are now discharged home in 3 or 4 days. This trend toward a shorter hospital stay requires better patient education and a reasonable home environment to which the patient can be safely and comfortably discharged. The surgeon must also carefully evaluate the patient before discharge and resist pressure from insurance companies and hospital administrators when the patient's condition indicates that she is not suitable for an early discharge. The patient and her family must be instructed on proper care. Can she take a bath? Can she go up and down the stairs? Can she pick up her grandchild? How soon can she drive a car? A printed set of instructions for home care as well as answers to frequently asked questions are good ideas. Liberal use of home visiting nurses is also recommended, especially in older or more debilitated patients or in those whose home situation may be less than ideal.

COMPLICATIONS

Complications from hysterectomy can be diagnosed intraoperatively or postoperatively. In a thorough review, Harris found an overall complication rate of up to 50% associated with abdominal hysterectomy, but serious complications requiring reoperation or long-term disability are relatively uncommon. Reoperation rates of 4% to 4.3% have been reported by Gambone and associates and Browne and Frazer. The most common complications include infection, hemorrhage, and injuries to adjacent organs ([Table 32A.5](#)). Prevention and management of hemorrhage, infection, and operative injury complications are extensively discussed in several chapters of this text. Good surgical training, proper patient selection, knowledge of the anatomy, and good surgical judgment—which includes knowing your personal skills and limits—are all keys to minimizing complications.

Several factors have been consistently shown to be associated with an increased risk of complications related to hysterectomy. These are increasing age, medical illness, obesity, and malignancy. These conditions are beyond the control of the gynecologic surgeon, but they should be considered in the risk:benefit ratio when considering surgery, and every effort

P.712

should be made to have the patient in the best possible condition at the time of surgery.

TABLE 32A.5 Complications of Hysterectomy

COMPLICATION	ABDOMINAL	VAGINAL	LAPAROSCOPICALLY ASSISTED VAGINAL
<i>Bleeding</i>			
Hemorrhage	1%-2%	1%-5%	1%
Transfusion	2%-12%	2%-8.3%	1.58%
<i>Infection</i>			

Unexplained fever	10%-20%	5%-8%	2.14%
Operative site	6.6%-24.7%	3.9%-10%	0.54%
Wound	4%-8%	NA	NA
Pelvic	3.2%-10%	3.9%-10%	1.27%
Urinary tract	1.1%-5%	1.7%-5%	0.81%
Pneumonia	0.4%-2.6%	0.29%-2%	0.11%
<hr/>			
<i>Injuries</i>			
Bladder	1%-2%	0.5%-1.5%	1%
Bowel	0.1%-1%	0.1%-0.8%	0.1%-1%
Ureter	0.1%-0.5%	0.05%- 0.1%	0.19%
Vesicovaginal fistula	0.1%-0.2%	0.1%-0.2%	0.22%
Trocar injuries	—	—	0.5%

From Harris WJ. Early complications of abdominal and vaginal hysterectomy. *Obstet Gynecol Surv* 1995;50:795, with permission.

BEST SURGICAL PRACTICES

- Hysterectomy is one of the most common major operations performed in the United States. The most common indications are uterine leiomyoma, endometriosis, abnormal uterine bleeding, and malignancy. There are many techniques to perform a hysterectomy, including abdominal, vaginal, laparoscopic and laparoscopically assisted, total, and subtotal. Before surgery, the surgeon should discuss the indications, other management options, choice of surgical approach, risks and potential complications of surgery, and expected outcomes with the patient and her supporters and obtain a fully informed operative consent.
- Numerous prospective randomized studies have shown that total abdominal hysterectomy results in the same or better postoperative sexual function, urinary tract and bowel function, and pelvic support as does supracervical hysterectomy.
- Prophylactic antibiotics administered within 1 hour before the initial incision significantly reduce the risk of a surgical site infection. There is no advantage to continuing antibiotics after surgery in an uninfected patient.
- The surgeon and the surgical team should be completely focused on the operation. Thoughtful preoperative

preparation, careful surgical technique, well-reasoned judgment intraoperatively, and attentive postoperative care by a well-trained and interactive team will result in the best outcomes. Good communication between all members of the team is of great importance.

- We have found that the surgical techniques described in this chapter have been highly effective, but each surgeon should be familiar with a number of variations of standard hysterectomy technique and use appropriate variations that might suit the anatomy or pathology of a specific patient.

BIBLIOGRAPHY

Abdel-Fattah M, Barrington J, Yousef M, et al. Effect of total abdominal hysterectomy on pelvic floor function. *Obstet Gynecol Surv* 2004;59:299.

Adelman MR, Bardsley TR, Sharp HT. Urinary tract injuries in laparoscopic hysterectomy: a systematic review. *J Minim Invasive Gynecol* 2014;21:558. pii: S1553-4650(14)00036-3.

Alessandri F, Mistrangelo E, Lijoi D, et al. A prospective, randomized trial comparing immediate versus delayed catheter removal following hysterectomy. *Acta Obstet Gynecol Scand* 2006;85:716.

Allen WM, Masters WH. Traumatic laceration of uterine support: the clinical syndrome and the operative treatment. *Am J Obstet Gynecol* 1955;70:500.

American College of Obstetricians and Gynecologists. *ACOG Practice Bulletin No. 96: Alternatives to hysterectomy in the management of leiomyomas*. Washington, DC: ACOG, 2008.

American College of Obstetricians and Gynecologists. *ACOG Practice Bulletin No. 104: Antibiotic prophylaxis for gynecologic procedures*. Washington, DC: ACOG, 2009.

American College of Obstetricians and Gynecologists. *ACOG Practice Bulletin No. 578: Elective surgery and patient choice*. Washington, DC: ACOG, 2013.

American College of Obstetricians and Gynecologists. *ACOG Practice Bulletin No. 464: Patient safety in the surgical environment*. Washington, DC: ACOG, 2012.

American College of Obstetricians and Gynecologists. *ACOG Practice Bulletin No. 21: Prevention of deep vein thrombosis and pulmonary embolism*. Washington, DC: ACOG, 2000.

American College of Obstetricians and Gynecologists. *ACOG Practice Bulletin No. 7: Prophylactic oophorectomy*. Washington, DC: ACOG, 1999.

American College of Obstetricians and Gynecologists. *ACOG Practice Bulletin No. 571: Solutions for surgical preparation of the vagina*. Washington, DC: ACOG, 2013.

Asante A, Whiteman MK, Kulkarni A, et al. Elective oophorectomy in the United States: trends and in-hospital complications, 1998-2006. *Obstet Gynecol* 2010;16:1088.

Azari L, Santoso JT, Osborne SE. Optimal pain management in total abdominal hysterectomy. *Obstet Gynecol Surv* 2013;68:215.

Averette HE, Nguyen HN. The role of prophylactic oophorectomy in cancer prevention. *Gynecol Oncol* 1994;55:S38.

P.713

Babalola EO, Bharucha AE, Schleck CD, et al. Decreasing utilization of hysterectomy: a population-based study in Olmsted County, Minnesota, 1965-2002. *Am J Obstet Gynecol* 2007;196:214.

Bhattacharya S, Middleton LJ, Tsourapas A, et al. Hysterectomy, endometrial ablation and Mirena® for heavy menstrual bleeding: a systematic review of clinical effectiveness and cost-effectiveness analysis. *Health Technol Assess* 2011;15:iii, 1.

Bottle A, Aylin P. Variations in vaginal and abdominal hysterectomy by region and trust in England. *BJOG* 2005;112:326.

Bridgman S, Dobbins J, Casbard A. The VALUE national hysterectomy study: description of the patients and their surgery. *BJOG* 2002; 109:302.

Broder MS, Kanouse DE, Mittman BS, et al. The appropriateness of recommendations for hysterectomy. *Obstet Gynecol* 2000;95:199.

Brooks P, Clouse J, Morris L. Hysterectomy vs. resectoscopic endometrial ablation for the control of abnormal uterine bleeding: a costcomparative study. *J Reprod Med* 1994;39:755.

Brummer TH, Heikkinen AM, Jalkanen J, et al. Antibiotic prophylaxis for hysterectomy, a prospective cohort study: cefuroxime, metronidazole, or both? *BJOG* 2013;120:1269.

Brummer TH, Jalkanen J, Fraser J, et al. FINHYST, a prospective study of 5279 hysterectomies: complications and their risk factors. *Hum Reprod* 2011;26:1741.

Bukovsky I, Liftshitz Y, Langer R, et al. Ovarian residual syndrome. *Surg Gynecol Obstet* 1988;167:132.

Carlson K, Miller B, Fowler F. The Maine Women's Health Study: I. Outcomes of hysterectomy. *Obstet Gynecol* 1994;83:556.

Carlson K, Miller B, Fowler F. The Maine Women's Health Study: II. Outcomes of non-surgical management of leiomyomas, abnormal bleeding, and chronic pelvic pain. *Obstet Gynecol* 1994;83:566.

Carlson K, Nichols D, Schiff I. Indications for hysterectomy. *N Engl J Med* 1993;328:856.

Casiano ER, Trabuco EC, Bharucha AE, et al. Risk of oophorectomy after hysterectomy. *Obstet Gynecol* 2013;121:1069.

Castelo-Branco C, Figueras F, Sanjuan A, et al. Long-term compliance with estrogen replacement therapy in surgical postmenopausal women: benefits to bone and analysis of factors associated with discontinuation. *Menopause* 1999;6:307.

Ceccaroni M, Berretta R, Malzoni M, et al. Vaginal cuff dehiscence after hysterectomy: a multicenter retrospective study. *Eur J Obstet Gynecol Reprod Biol* 2011;158:308.

Chamsy DJ, Louie MY, Lum DA, et al. Clinical utility of postoperative hemoglobin level testing following total laparoscopic hysterectomy. *Am J Obstet Gynecol* 2014;211:224.e1. pii: S0002-9378(14)00341-X. doi:10.1016/j.ajog.2014.04.003

Clarke A, Black N, Rowe P, et al. Indications for and outcome of total abdominal hysterectomy for benign disease: a prospective cohort study. *BJOG* 1995;102:611.

Clarke-Pearson DL, Geller EJ. Complications of hysterectomy. *Obstet Gynecol* 2013;121:654.

Clifford V, Daley A. Antibiotic prophylaxis in obstetric and gynaecological procedures: a review. *Aust N Z J Obstet Gynaecol* 2012;52:412.

Darai E, Soriano D, Kimata P, et al. Vaginal hysterectomy for enlarged uteri, with or without laparoscopic assistance: randomized study. *Obstet Gynecol* 2001;97:712.

Dickson E, Argenta PA, Reichert JA. Results of introducing a rapid recovery program for total abdominal hysterectomy. *Gynecol Obstet Invest* 2012;73:21.

Dorsey J, Steinberg E, Holtz P. Clinical indications for hysterectomy route: patient characteristics or physician preference? *Am J Obstet Gynecol* 1995;173:1452.

Dorsey JH, Holtz PM, Griffiths RI, et al. Costs and charges associated with three alternative techniques of hysterectomy. *N Engl J Med* 1996;335:476.

Duhan N. Current and emerging treatments for uterine myoma—an update. *Int J Womens Health* 2011;3:231.

Einarsson JI, Suzuki Y, Vellinga TT, et al. Prospective evaluation of quality of life in total versus supracervical laparoscopic hysterectomy. *J Minim Invasive Gynecol* 2011;18:617.

Ewen S, Sutton C. Initial experience with supracervical laparoscopic hysterectomy and removal of the cervical transformation zone. *BJOG* 1994;101:225.

Fatania K, Vithayathil M, Newbold P, et al. Vaginal versus abdominal hysterectomy for the enlarged non-prolapsed uterus: a retrospective cohort study. *Eur J Obstet Gynecol Reprod Biol* 2014; 174:111.

Fong YF, Lim FK, Arulkumaran S. Prophylactic oophorectomy: a continuing controversy. *Obstet Gynecol*

Surv 1998;53:493.

Franchi M, Ghezzi F, Zanaboni F, et al. Nonclosure of peritoneum at radical abdominal hysterectomy and pelvic node dissection: a randomized study. *Obstet Gynecol* 1997;90:622.

Garry R. The future of hysterectomy. *BJOG* 2005;112:133.

Gill SE, Mills BB. Physician opinions regarding elective bilateral salpingectomy with hysterectomy and for sterilization. *J Minim Invasive Gynecol* 2013;20:517.

Gimbel H. Total or subtotal hysterectomy for benign uterine diseases? A meta-analysis. *Acta Obstet Gynecol Scand* 2007;86:133.

Gimbel H, Zobbe V, Andersen BM, et al. Randomised controlled trial of total compared with subtotal hysterectomy with one-year follow up results. *BJOG* 2003;110:1088.

Goldman JA, Feldberg D, Dicker D, et al. Femoral neuropathy subsequent to abdominal hysterectomy: a comparative study. *Eur J Obstet Gynecol Reprod Biol* 1985;20:385.

Grosse-Drieling D, Schlutius JC, Altgassen C, et al. Laparoscopic supracervical hysterectomy (LASH), a retrospective study of 1,584 cases regarding intra- and perioperative complications. *Arch Gynecol Obstet* 2012;285:1391.

Harris M, Olive D. Changing hysterectomy patterns after introduction of laparoscopically assisted vaginal hysterectomy. *Am J Obstet Gynecol* 1994;171:340.

Hasson HM. Cervical removal at hysterectomy for benign disease: risks and benefits. *J Reprod Med* 1993;38:781.

Hillis S, Marchbanks P, Peterson H. The effectiveness of hysterectomy for chronic pelvic pain. *Obstet Gynecol* 1995;86:941.

Hillis S, Marchbanks P, Peterson H. Uterine size and risks of complications among women undergoing abdominal hysterectomy for leiomyomas. *Obstet Gynecol* 1996;87:539.

Horbach NS, Lee TTM, Levy BS, et al. Unraveling the myths of laparoscopic supracervical hysterectomy. *Cont OB/GYN* 2006.

Howard F. The role of laparoscopy in chronic pelvic pain: promise and pitfalls. *Obstet Gynecol Surv* 1993;48:357.

Irwin KL, Weiss NS, Lee NC, et al. Tubal sterilization, hysterectomy, and the subsequent occurrence of epithelial ovarian cancer. *Am J Epidemiol* 1991;134:363.

Islam MS, Protic O, Giannubilo SR, et al. Uterine leiomyoma: available medical treatments and new possible

therapeutic options. *J Clin Endocrinol Metab* 2013;98:921.

Jacobs I, Oram D. Prevention of ovarian cancer: a survey of the practice of prophylactic oophorectomy by fellows and members of the Royal College of Obstetricians and Gynaecologists. *BJOG* 1989;96:510.

Jacobson GF, Shaber RE, Armstrong MA, et al. Hysterectomy rates for benign indications. *Obstet Gynecol* 2006;107:1278.

Janssen PF, Brölmann HA, van Kesteren PJ, et al. Perioperative outcomes using LigaSure compared with conventional bipolar instruments in laparoscopic hysterectomy: a randomised controlled trial. *BJOG* 2011;118:1568.

Johnson N, Barlow D, Lethaby A, et al. Surgical approach to hysterectomy for benign gynaecological disease. *Cochrane Database Syst Rev* 2006;(19):CD003677.

Kauf ND, Satagopan JM, Robson ME, et al. Risk-reducing salpingo-oophorectomy in women with a BRCA1 or BRCA2 mutation. *N Engl J Med* 2002;356:1609.

Kelly HA. *Operative gynecology*. New York, NY: Appleton, 1896.

Kelly HA, Cullen TS. *Myomata of the uterus*. Philadelphia, PA: WB Saunders, 1909.

Kelly HA, Noble CP. *Gynecology and abdominal surgery*, vol. 1. Philadelphia, PA: WB Saunders, 1907.

Kerber IJ, Turner RJ. Ovaries, estrogen, and longevity and long-term mortality associated with oophorectomy compared with ovarian conservation in the Nurses' Health Study and variation in ovarian conservation in women undergoing hysterectomy for benign indications. *Obstet Gynecol* 2013;122:397.

Kohli N, Mallipeddi PK, Neff JM, et al. Routine hematocrit after elective gynecologic surgery. *Obstet Gynecol* 2000;95:847.

P.714

Korkontzelos I, Gkioulekas N, Stamatopoulos C, et al. Complicated abdominal hysterectomy subsequent to uterine embolization for large fibroids. *Clin Exp Obstet Gynecol* 2012;39:122.

Kovac SR. Clinical opinion: guidelines for hysterectomy. *Am J Obstet Gynecol* 2004;191:635.

Kovac SR. Hysterectomy outcomes in patients with similar indications. *Obstet Gynecol* 2000;95:787.

Krizova A, Clarke BA, Bernardini MQ, et al. Histologic artifacts in abdominal, vaginal, laparoscopic, and robotic hysterectomy specimens: a blinded, retrospective review. *Am J Surg Pathol* 2011; 35:115.

Kuppermann M, Varner RE, Summitt RL, et al. Effect of hysterectomy versus medical treatment on health-related quality of life and sexual function. *Obstet Gynecol Surv* 2004;59:706.

Landeem LB, Bell MC, Hubert HB, et al. Clinical and cost comparisons for hysterectomy via abdominal, standard laparoscopic, vaginal and robot-assisted approaches. *S D Med* 2011;64:197, 201, 203 passim.

Learman LA. Hysterectomy 2014: indications and techniques. *Clin Obstet Gynecol* 2014;57:1.

Learman LA, Summitt RL Jr, Varner RE, et al. Total or Supracervical Hysterectomy (TOSH) Research Group. A randomized comparison of total or supracervical hysterectomy: surgical complications and clinical outcomes. *Obstet Gynecol* 2003;102:453.

Lofgren M, Poromaa IS, Stjerndahl JH, et al. Postoperative infections and antibiotic prophylaxis for hysterectomy in Sweden: a study by the Swedish National Register for Gynecologic Surgery. *Acta Obstet Gynecol Scand* 2004;83:1202.

Lonnee-Hoffmann RA, Schei B, Eriksson NH. Sexual experience of partners after hysterectomy, comparing subtotal with total abdominal hysterectomy. *Acta Obstet Gynecol Scand* 2006;85:1389.

Lykke R, Blaakær J, Ottesen B, et al. Hysterectomy in Denmark 1977-2011: changes in rate, indications, and hospitalization. *Eur J Obstet Gynecol Reprod Biol* 2013;171:333.

Lynch HT, Lynch PM. Tumor variation in the cancer family syndrome: ovarian cancer. *Am J Surg* 1979;138:439.

Lyons TL. Laparoscopic supracervical hysterectomy. *Obstet Gynecol Clin North Am* 2000;27:441.

Mahdi H, Goodrich S, Lockhart D, et al. Predictors of surgical site infection in women undergoing hysterectomy for benign gynecologic disease: a multicenter analysis using the National Surgical Quality Improvement Program data. *J Minim Invasive Gynecol* 2014;21:901. pii: S1553-4650(14)00249-0. doi:10.1016/j.jmig.2014.04.003

Mamik MM, Antosh D, White DE, et al. Risk factors for lower urinary tract injury at the time of hysterectomy for benign reasons. *Int Urogynecol J* 2014;25:1031.

Matteson KA, Peipert JF, Hirway P, et al. Factors associated with increased charges for hysterectomy. *Obstet Gynecol* 2006;107:1057.

Mikhail E, Miladinovic B, Finan M. The relationship between obesity and trends of the routes of hysterectomy for benign indications. *Obstet Gynecol* 2014;123:126S. doi:10.1097/01.AOG.0000447087.18352.06

Morgan K, Thomas E. Nerve injury at abdominal hysterectomy. *BJOG* 1995;102:665.

Muffly TM, Ridgeway B, Abbott S, et al. Small bowel obstruction after hysterectomy to treat benign disease. *J Minim Invasive Gynecol* 2012;19:615.

Munro MG. Management of heavy menstrual bleeding: is hysterectomy the radical mastectomy of gynecology? *Clin Obstet Gynecol* 2007;50:324.

Myers ER, Steege JF. Risk adjustment for complications of hysterectomy: limitations of routinely collected administrative data. *Am J Obstet Gynecol* 1999;181:567.

Nichols DH, Willey PS, Randall CL. Significance of restoration of normal vaginal depth and axis. *Obstet Gynecol* 1970;36:251.

Nieboer TE, Hendriks JC, Bongers MY, et al. Quality of life after laparoscopic and abdominal hysterectomy: a randomized controlled trial. *Obstet Gynecol* 2012;119:85.

Ostrzenski A. A new, simplified posterior culdoplasty and vaginal vault suspension during abdominal hysterectomy. *Int J Obstet Gynecol* 1995;49:25.

Ouldamer L, Rossard L, Arbion F, et al. Risk of incidental finding of endometrial cancer at the time of hysterectomy for benign condition. *J Minim Invasive Gynecol* 2014;21:131.

Parazzini F, Negri E, Vecchia C, et al. Hysterectomy, oophorectomy, and subsequent ovarian cancer risk. *Obstet Gynecol* 1993;81:363.

Park MJ, Kim YS, Rhim H, Lim HK. Safety and therapeutic efficacy of complete or near-complete ablation of symptomatic uterine fibroid tumors by MR imaging-guided high-intensity focused US therapy. *J Vasc Interv Radiol* 2014;25:231.

Peipert JF, Weitzen S, Cruickshank C, et al. Risk factors for febrile morbidity after hysterectomy. *Obstet Gynecol* 2004;103:86.

Perera HK, Ananth CV, Richards CA, et al. Variation in ovarian conservation in women undergoing hysterectomy for benign indications. *Obstet Gynecol* 2013;121:717.

Pinion S, Parkin D, Abramovich D, et al. Randomized trial of hysterectomy, endometrial ablation, and transcervical endometrial resection for dysfunctional uterine bleeding. *BMJ* 1994;309:979.

Pynnä K, Vuorela P, Lodenius L, et al. Cost-effectiveness of hysterectomy for benign gynecological conditions: a systematic review. *Acta Obstet Gynecol Scand* 2013;93:225. doi:10.1111/aogs.12299

Ramirez PT, Klemer DP. Vaginal evisceration after hysterectomy: a literature review. *Obstet Gynecol Surv* 2002;57:462.

Rebbeck TR, Lynch HT, Neuhausen SL, et al. Prophylactic oophorectomy in carriers of BRCA1 or BRCA2 mutations. *N Engl J Med* 2002;346:1616.

Ribeiro SC, Ribeiro RM, Santos NC, et al. A randomized study of total abdominal, vaginal and laparoscopic hysterectomy. *Int J Gynecol Obstet* 2003;83:37.

Rice MS, Hankinson SE, Tworoger SS. Tubal ligation, hysterectomy, unilateral oophorectomy, and risk of

ovarian cancer in the Nurses' Health Studies. *Fert Steril* 2014;102:192.

Richardson EH. A simplified technique for abdominal panhysterectomy. *Surg Obstet Gynecol* 1929;48:248.

Robertson D, Lefebvre G, Leyland N, et al. Adhesion prevention in gynaecological surgery. *J Obstet Gynaecol Can* 2010;32:598.

Schollmeyer T, Elessawy M, Chastamouratidhs B, et al. Hysterectomy trends over a 9-year period in an endoscopic teaching center. *Int J Gynaecol Obstet* 2014;126:45. pii: S0020-7292(14)00192-1.

Semm K. Endoscopic subtotal hysterectomy without colpotomy: classic intrafascial SEMM hysterectomy. A new method of hysterectomy by pelviscopy, laparotomy, per vaginam or functionally by total uterine mucosal ablation. *Int Surg* 1996;81:362.

Sharon A, Auslander R, Brandes-Klein O. Cystoscopy after total or subtotal laparoscopic hysterectomy: the value of a routine procedure. *Obstet Gynecol Surv* 2006;61:511.

Smorgick N, Patzkowsky KE, Hoffman MR, et al. The increasing use of robot-assisted approach for hysterectomy results in decreasing rates of abdominal hysterectomy and traditional laparoscopic hysterectomy. *Arch Gynecol Obstet* 2014;289:101.

Solnik MJ, Munro MG. Indications and alternatives to hysterectomy. *Clin Obstet Gynecol* 2014;57:14.

Solomon ER, Muffly TM, Barber MD. Common postoperative pulmonary complications after hysterectomy for benign indications. *Am J Obstet Gynecol* 2013;208:54.e1.

Song H, Lu D, Navaratnam K, Shi G. Aromatase inhibitors for uterine fibroids. *Cochrane Database Syst Rev* 2013;(10):CD009505. doi:10.1002/14651858.CD009505.pub2

Spilsbury K, Semmens JB, Hammond I, et al. Persistent high rates of hysterectomy in Western Australia: a population-based study of 83,000 procedures over 23 years. *BJOG* 2006;113:804.

Stovall T, Muneyyirci-Delale O, Summitt R, et al.; for the Leuprolide Acetate Study Group. GnRH agonist and iron versus placebo and iron in the anemic patient before surgery for leiomyomas: a randomized controlled trial. *Obstet Gynecol* 1995;86:65.

Surgical Care Improvement Project. *Prophylactic antibiotic regimen selection for surgery*. Available at: <http://www.medic.org/scip>

Symmonds RE, Pettit PDM. Ovarian remnant syndrome. *Obstet Gynecol* 1979;54:174.

Vierhout ME. Influence of nonradical hysterectomy on the function of the lower urinary tract. *Obstet Gynecol Surv* 2001;56:381.

Watson T. Vaginal cuff closure with abdominal hysterectomy: a new approach. *J Reprod Med* 1994;39:903.

Wijk L, Franzen K, Ljungqvist O, Nilsson K. Implementing a structured Enhanced Recovery After Surgery (ERAS) protocol reduces length of stay after abdominal hysterectomy. *Acta Obstet Gynecol Scand* 2014;93:749. doi:10.1111/aogs.12423

P.715

Wright JD, Ananth CV, Tergas AI, et al. An economic analysis of robotically assisted hysterectomy. *Obstet Gynecol* 2014;123:1038. doi:10.1097/AOG.0000000000000244

Wright JD, Herzog TJ, Tsui J, et al. Nationwide trends in the performance of inpatient hysterectomy in the United States. *Obstet Gynecol* 2013;122:233.

Zimmermann A, Bernuit D, Gerlinger C, et al. Prevalence, symptoms and management of uterine fibroids: an international internetbased survey of 21,746 women. *BMC Womens Health* 2012;12:6.
