Chapter 18
Operative Hysteroscopy

Mindy S. Christianson

Kyle J. Tobler

Howard A. Zacur

DEFINITIONS

Hysteroscopy—Direct visual inspection of the cervical canal and uterine cavity through a rigid or flexible hysteroscope.

Index of refraction—The bending of light caused by the ratio of its velocity in room air to its velocity within an optical fiber.

Resectoscope—A specialized electrosurgical endoscope that consists of an inner and outer sheath equipped with a 30-degree telescope. The inner sheath has a common channel for the telescope fluid medium and electrode.

Uterine synechiae—Adhesions that form between the anterior and posterior walls of the uterus as a result of trauma or infection in a milieu of estrogen deprivation.

INTRODUCTION

Hysteroscopy is a term derived from the Greek words *hystera,* which means uterus, and *skopeo,* which means "to view." In 1869, Pantaleoni successfully performed this procedure in a living human subject. He used a tube with an external light source to detect "vegetations within the uterine cavity." No attempt was made at this time to distend the uterine cavity. During the past 145 years, developments in optics, fiberoptics, instruments, and distending media have resulted in new equipment and techniques that allow the gynecologic surgeon to diagnose and treat many intrauterine cavity disorders. Hysteroscopy is a standard part of the gynecologic surgeon's armamentarium and the preferred minimally invasive choice for treatment of intrauterine pathology.

Abnormal vaginal bleeding may occur as the result of many different intrauterine cavity disorders. Dilating the endocervical canal and then blindly probing or curetting the uterine cavity to diagnose and treat these disorders would seem far less effective than performing a diagnostic and/or operative hysteroscopy. Critics have cautioned, however, about the risk of disseminating endometrial cells into the peritoneal cavity from the pressure of either gaseous or liquid distending medium during hysteroscopy. In 2000, reports by Zerbe and colleagues and Obermair and colleagues demonstrated that endometrial cancer cells could be found in peritoneal fluid following hysteroscopy with saline as distending medium in women with endometrial cancer. Whether to use hysteroscopy in evaluating abnormal bleeding in women at risk for endometrial cancer was questioned by the authors of these reports. A retrospective cohort analysis by Soucie and associates in 2012 linked a registry of women diagnosed with endometrial cancer with performance of hysteroscopy, staging of endometrial cancer, and death rates. This study concluded that hysteroscopy in women with endometrial cancer was not associated with causing a higher stage of disease. The authors concluded that hysteroscopy should continue to be used as a safe diagnostic tool for abnormal uterine bleeding.

With the emergence of minimally invasive gynecology surgery as a recognized advantage to patients, operative hysteroscopy has earned a special niche in this area. The advantages of hysteroscopy as an accurate diagnostic technique are that it not only allows direct visual observation and accurate localization of pathology but also provides a means to sample the site most likely to yield positive results. Hysteroscopy generally is a low-risk technique that uses the endocervical canal, the natural passageway of the body, to gain entry into the intrauterine environment. Commonly performed procedures utilizing hysteroscopy include diagnostic hysteroscopy, tubal sterilization, polypectomy, myomectomy, and excision of uterine septa. Nonhysteroscopic techniques to treat intrauterine septa and adhesions are obsolete. Ablation or resection of the endometrium is considered an acceptable alternative to hysterectomy for the management of abnormal uterine bleeding. Submucous myomas no longer require hysterectomy because they can be satisfactorily managed conservatively by operative hysteroscopy. Cornual obstruction and interstitial tubal obstruction also are now managed hysteroscopically. Teaching operative hysteroscopy techniques is a key aspect of residency training curriculums and postgraduate seminars. However, as operative hysteroscopy case numbers have increased, the number of complications has also risen. Most of these complications are caused by operator error and inexperience.

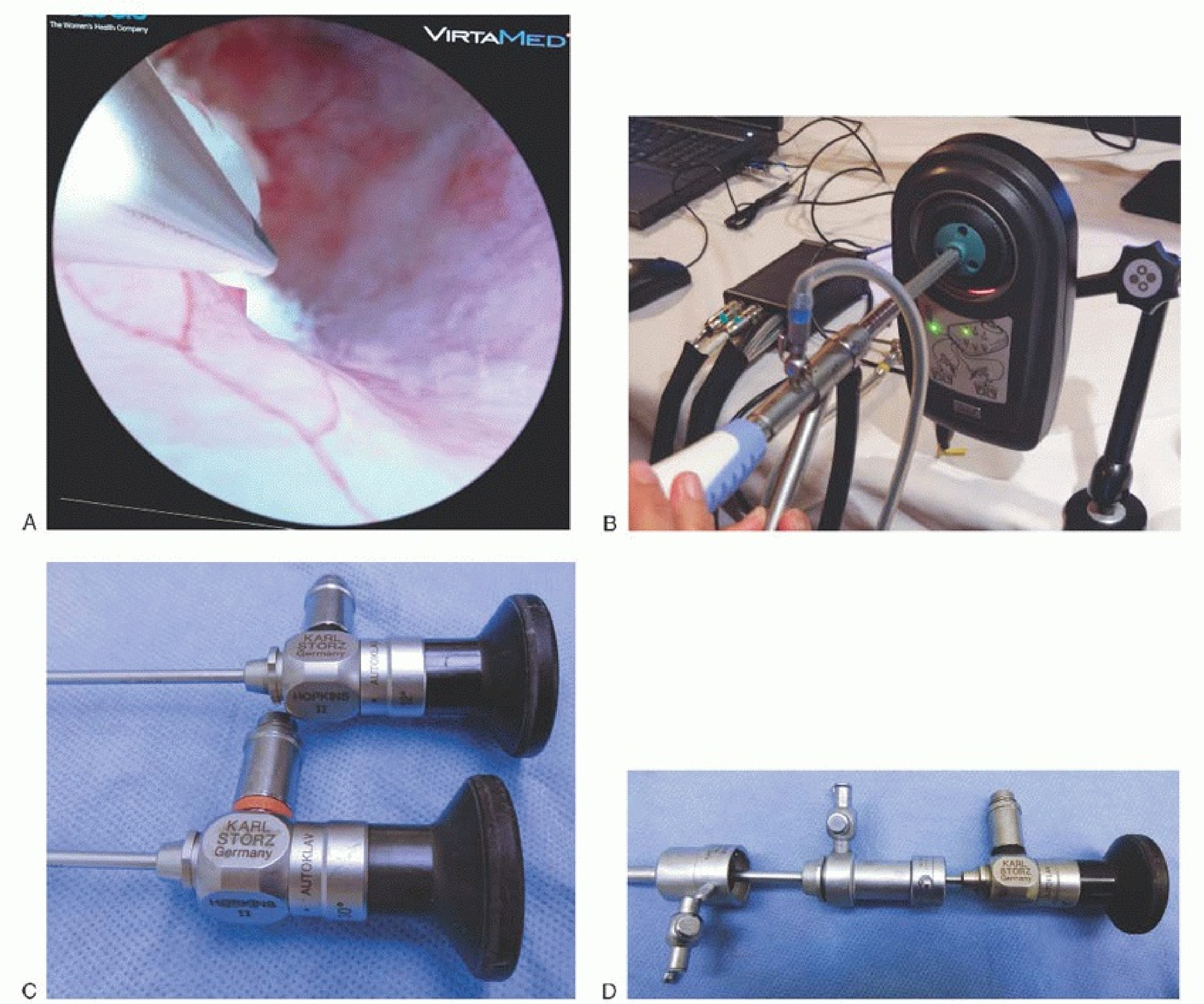

FIGURE 18.1 A: Computerized simulation permits the gynecologist to interact by manipulating a hysteroscopic morcellator and resecting a virtual submucosal myoma or polyp. **B:** The simulator uses equipment that is balanced similar to actual hysteroscopes. **C:** Two common 4-mm telescopes are shown here. *Top* is a 12-degree, and the *bottom* is a 30-degree telescope. **D:** Telescopes must couple to a 5-mm sheath to be practically functional. The distention liquid or gaseous medium gains access to the uterine cavity via the inner sheath, and fluid exits the uterus via the outer sheath.

Learning how to perform an adequate hysteroscopy and then becoming competent to do hysteroscopic surgery are practice, skill-related techniques. Older methods of acquiring endoscopic skills focused on course attendance, preceptorship, and practice. During the late 1990s and continuing to the present, simulators have been developed to facilitate hand-eye coordination exercises. Several of the computer-based models with advanced interactive graphics provide sophisticated models for the student to shave myomas, ablate endometrium, and pass cannulas into tubal ostia (**Fig. 18.1A**, **B**).

However, the most basic skill levels a hysteroscopist must attain are the ability to insert the scope safely into the uterine cavity followed by satisfactory distension of the cavity to obtain clear visualization of that cavity. The preceding is not taught by simulation and must be learned in vivo. Without this skill set, hysteroscopy cannot be successfully performed.

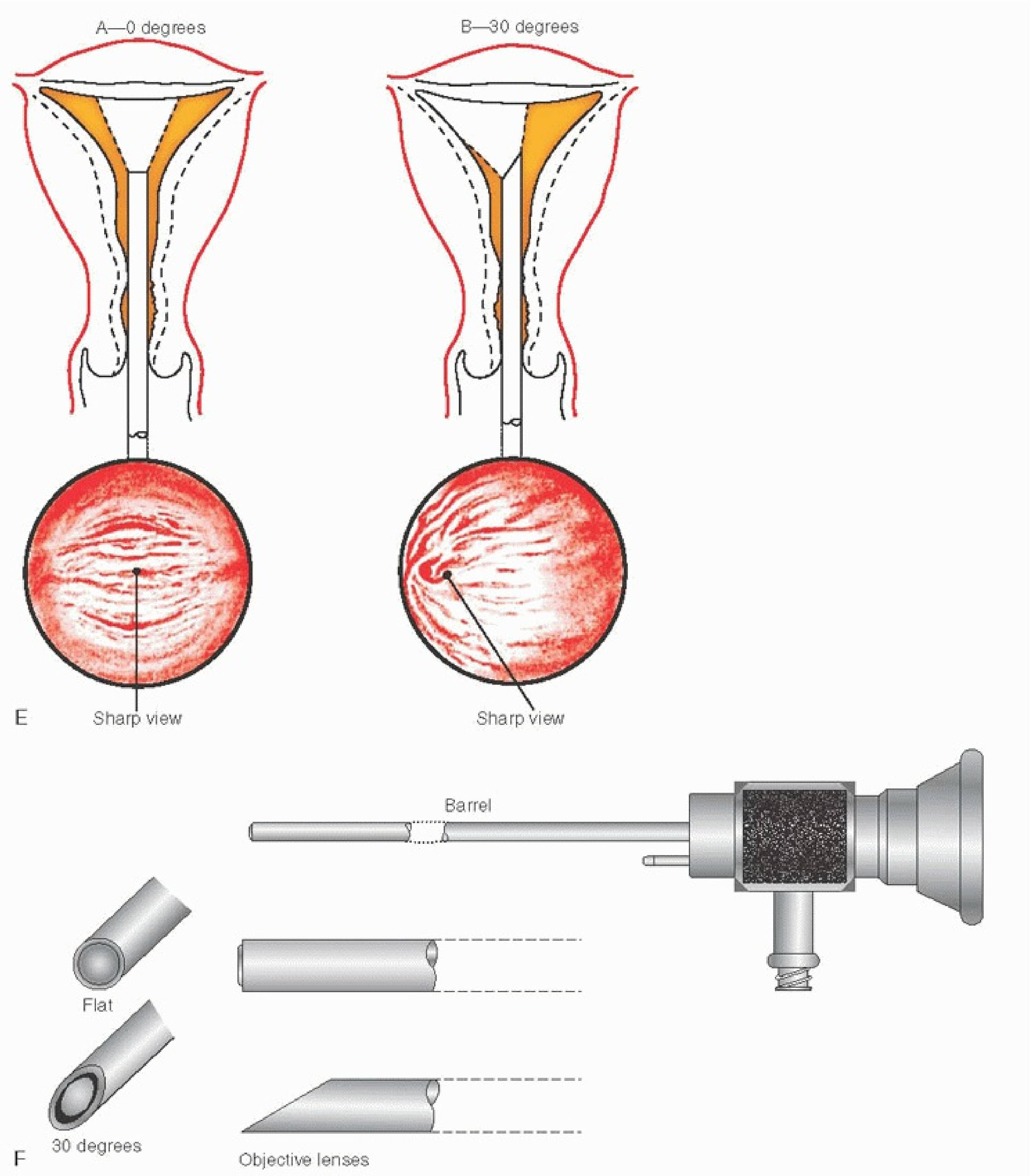

FIGURE 18.1 (*Continued*) **E:** Telescopes are available with either straight-on (0 degrees) or foreoblique (30 degrees) viewing objective lenses. **F:** A telescope can be conveniently subdivided into three parts: eyepiece, barrel, and objective lens. (Parts A and E reprinted from Baggish MS, Valle RF, Guedj H. *Hysteroscopy: visual perspectives of uterine anatomy, physiology and pathology,* 3rd ed. Philadelphia, PA: Lippincott Williams &

Wilkins, 2007, with permission. Copyright © 2007, Lippincott Williams.)

INSTRUMENTATION

Hysteroscopes may be classified as rigid or flexible and possessing fixed or variable focus and be designated for either diagnostic or operative use. Scope diameter, lens offset, sheath diameter, ability to be used with a variety of distending media,

and ability to use either bipolar or monopolar cautery are key characteristics of the instrumentation.

FIGURE 18.2 Contemporary operative hysteroscopy is performed with a digital camera attached to the eyepiece of the telescope. The operator and assistants all view the field by way of a high-resolution video monitor.

Viewing through the hysteroscopic telescope may still be done by using the naked eye, but is now almost always done by using a camera and video screen. As might be expected, the images obtained by the hysteroscope may vary depending upon the type of camera and video screen used with highdefinition systems providing the sharpest images (**Fig. 18.2**).

Telescopes

The telescope has three parts: the eyepiece, the barrel, and the objective lens (**Fig. 18.1F**). The 4-mm telescope (lens) gives the sharpest, clearest image in addition to a small outside diameter (**Fig. 18.1C**). The most desirable optics provide a large field that subtends an angle of approximately 105 degrees. However, 3-mm diameter telescopes, which have greatly improved optics, provide comparable views. These contemporary 3-mm diameter telescopes coupled to endoscopic video systems with zoom lenses are highly satisfactory for office hysteroscopy as well as for operative hysteroscopy. Telescopes are available in a variety of viewing angles with the 0-degree straight-on or a 30-degree fore-oblique view being the most common (**Fig. 18.1E**). Other viewing angles available include 12 degrees, 15 degrees, and 70 degrees. The major advantage of the 0-degree lens is that it allows the operator to see operative devices as a relatively distant panorama, whereas this view is lost when 30-degree lens is used. Surrounding the optics are numerous small-diameter incoherent fiberoptic bundles that provide intense cold illumination to the operative field.

Light Generators

The quality and power of light delivered to the telescope depend on the wattage and characteristics of the remote light generator and the type and structural integrity of the connecting fiberoptic light cable. Three general types of light generators are available: tungsten, metal halide, and xenon. The xenon white light is a powerful generator that provides high-quality color and intensity and is the most commonly used today.

Fiberoptic light cables must be intact to convey the optimal light from the generator to the telescope. Broken fibers can be easily identified by viewing the stretched-out cable against a dark background and looking for light emitting through the sides of the cable. The liquid cable conducts light effectively and provides superior light when combined with a xenon generator.

Diagnostic and Operative Sheaths

A diagnostic sheath is required to deliver the distending medium into the uterine cavity. The telescope fits into the sheath and is secured by means of a watertight seal that locks into place. The sheath is 4 to 5 mm in diameter, depending on the outer diameter of the telescope, with a 1-mm clearance between the inner wall and the telescope, through which either carbon dioxide (CO_2) or liquid distending medium is transmitted (**Fig. 18.1D**). Medium instillation into the sheath is controlled by means of an external stopcock. Even the 5-mm instrument allows easy access through the narrow endocervical canal past the point of maximal constriction, the internal os. Therefore, diagnostic hysteroscopy usually can be performed without cervical canal dilatation. If the hysteroscope is inserted into the canal under direct vision, and if the axis of the cervical and uterine canal is carefully followed until the corpus is reached, there should be no risk of creating a false passage or perforation. Imprecise or loose coupling between the telescope and sheath will result in leakage of the medium at that interface.

Operative sheaths have a larger diameter than do diagnostic sheaths, ranging in size from 7 to 10 mm and average 8 mm in diameter (**Fig. 18.3**). The operative sheath allows space for instillation of the medium, for the 3- to 4-mm telescope, and for the insertion of operating devices. The operating channel is sealed with a rubber nipple or gasket to prevent leakage of the distending medium (**Fig. 18.3C**). The standard operating sheath consists of a single common cavity shared by the medium, telescope, and operating tools. Disadvantages of this type of sheath are inability to flush the uterine cavity with the distending medium and difficulty manipulating the operative tools within the cavity. Hysteroscopes with isolated channels overcome the problems inherent to the common cavity sheath (**Fig. 18.4**). The dual operating channels permit flushing of the cavity and precise placement of operating accessories. A popular model today is the isolated-channel sheath consisting of a double-flushing sheath (**Fig. 18.4D, E**) that permits media instillation by way of the inner sheath and media return by way of the perforated outer sheath. The constant flow of the fluid medium in and out of the cavity creates a very clear operative field. The single isolated operating channel has a diameter sufficiently large (3 mm) to permit an entirely new generation of larger, sturdier operating tools to be used (**Fig. 18.4**). The new sheath combines the advantages of the resectoscope with the facility of the operating hysteroscope.

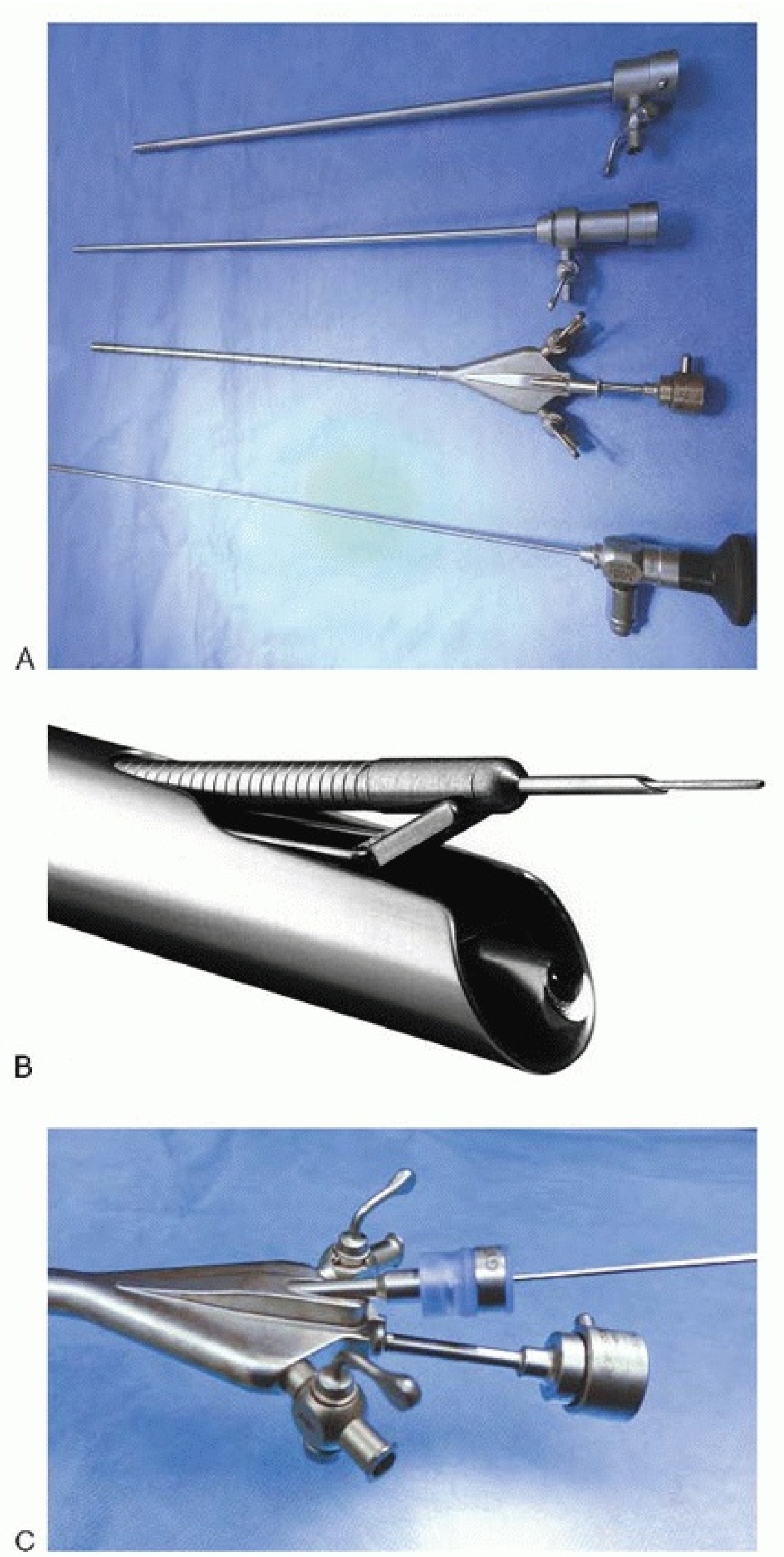

FIGURE 18.3 A: Instrumentation for hysteroscopic procedures. From top down: outer sheath of the diagnostic scope; the inner sheath of the diagnostic scope (not coupled together); operative sheath that includes inflow, outflow, and an instrument port; 4-mm telescope capable of insertion into either the operative sheath or diagnostic sheath. **B:** The terminal bridge reflects the cannula to angulate and facilitate its entry into the tubal ostium. (Reprinted from Baggish MS, Valle RF, Guedj H. *Hysteroscopy: Visual perspectives of uterine anatomy, physiology and pathology,* 3rd ed. Philadelphia, PA: Lippincott Williams & Wilkins, 2007, with permission. Copyright © 2007, Lippincott Williams.) **C:** An operating sheath with input and output channels as well as flushing capability. The operating channel is sealed with a rubber nipple and has a 7-F instrument inserted.

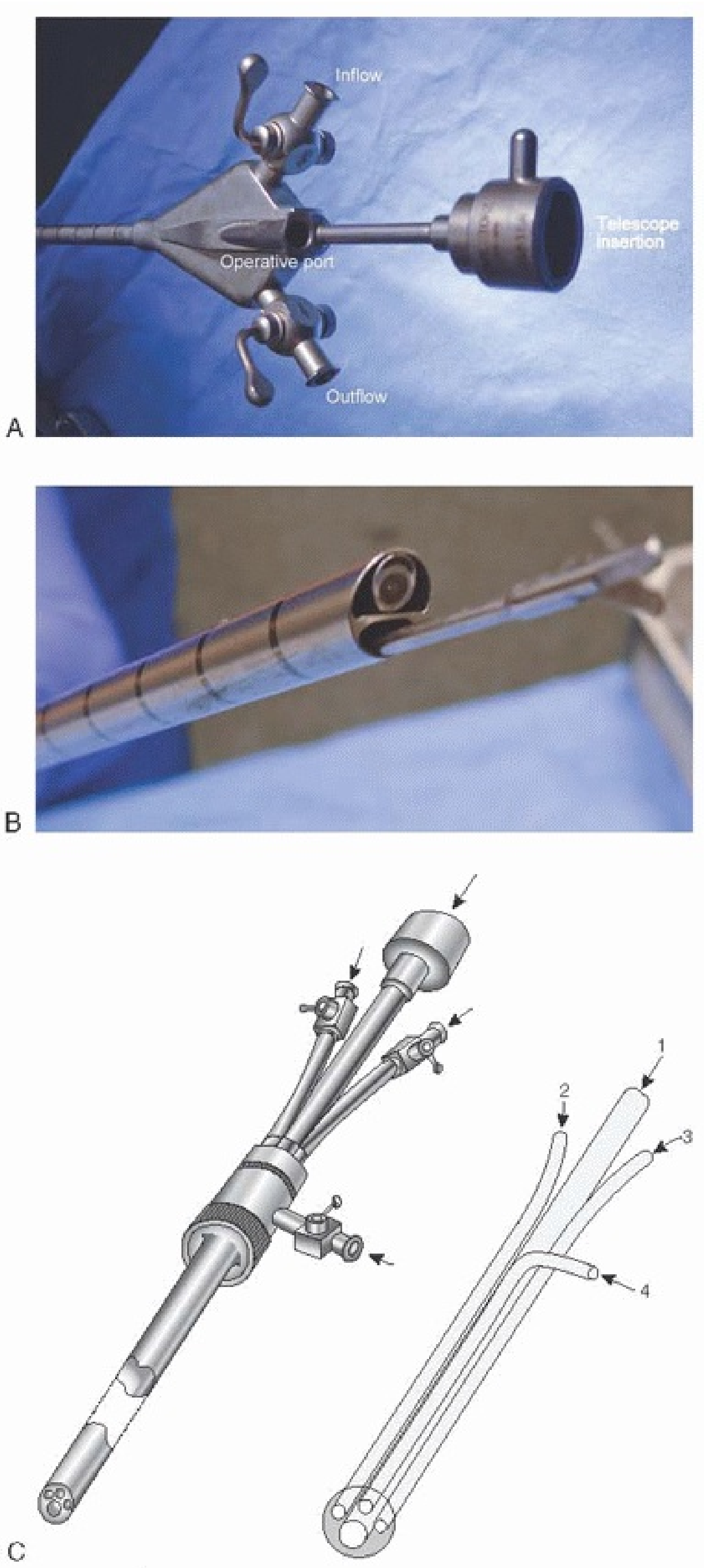

FIGURE 18.4 A: A single-channel operating sheath consists of a single cavity that the telescope, distending medium, and operating instruments share. **B:** Terminal portion of the operative sheath with scissors extended through. The top channel allows placement of the telescope, inflow, and outflow. The lower port allows passage of the operative instrument. **C:** A dual-channel operating sheath is constructed with (*1*) isolated channels for a telescope, (*2* and *3*) two operating devices, and (*4*) distending medium.

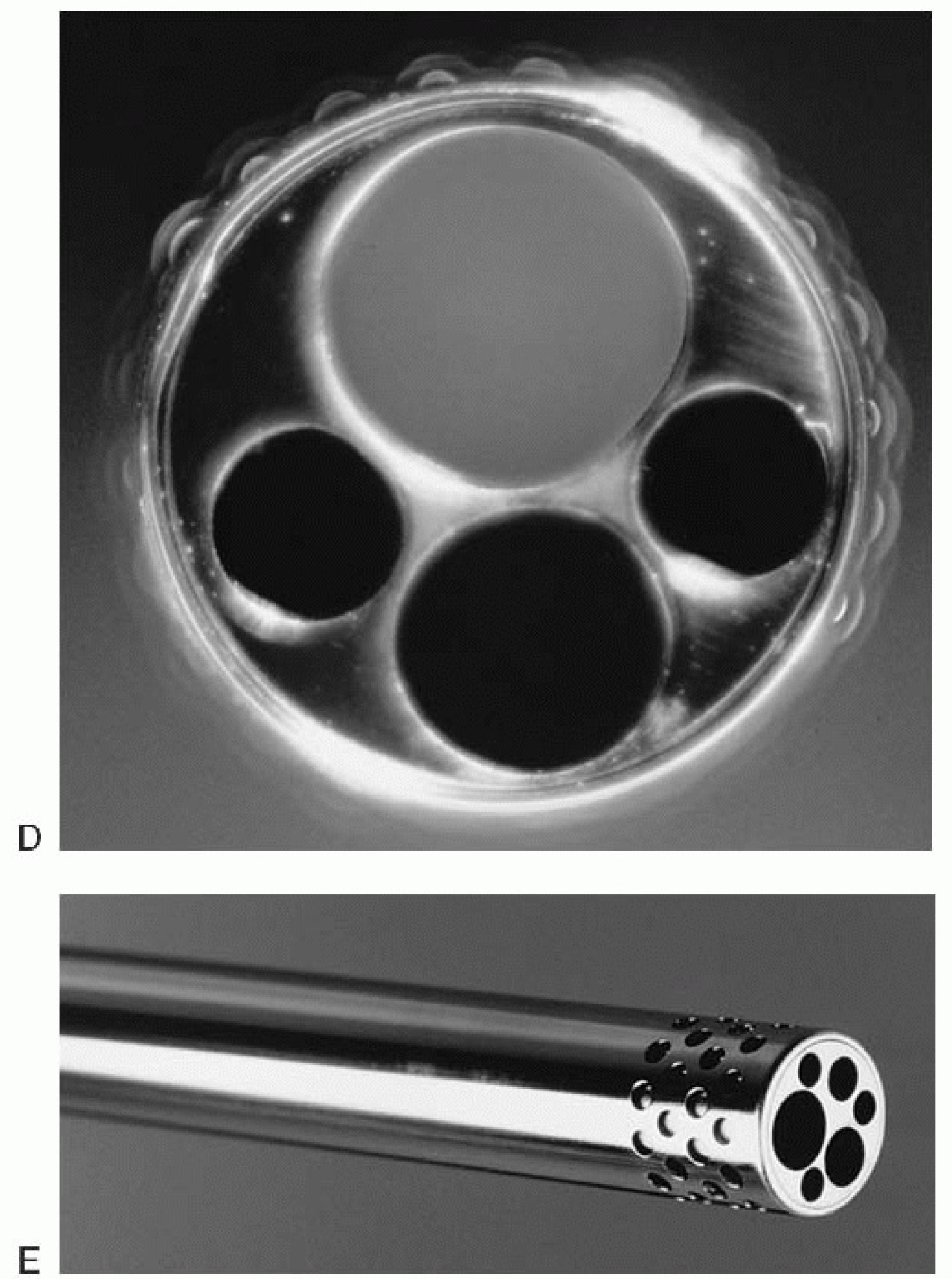

FIGURE 18.4 (*Continued*) **D:** The terminal portion of the secondgeneration isolated-channel hysteroscope shows the channel for the 4-mm optic **(top)** and a 3-mm operating channel for a variety of large accessory instruments **(bottom)**. The two channels at either side are the fluid intake channels. **E:** The double sheath mechanism of the isolated-channel hysteroscope. The perforations in the outer sheath are for fluid return. The uterus is continuously flushed.

The resectoscope is a specialized electrosurgical (monopolar or bipolar) endoscope that consists of an inner sheath and outer sheath (**Fig. 18.5A**). The outer sheath is for fluid return as described above. The inner sheath has a common channel for the telescope, fluid medium, and electrode (**Fig. 18.5B**). The double-armed electrode is fitted to a trigger device that pushes the electrode out beyond the sheath and then pulls it back within the sheath (**Fig. 18.5C**). The operating tools consist of four basic electrodes: a cutting loop, ball, button, and angulated needle (**Fig. 18.5D-G**). Most resectoscopes are equipped with a 30-degree telescope. The lens is angled toward the electrode to permit a clear view of the near operative field. Vision of the electrode is lost when the electrode is fully extended outward. Most operating sheaths measure 8 mm or more in outer diameter, so dilatation is usually required for insertion. Contemporary small-diameter resectoscopes use a 3-mm telescope and a 7- to 7.5-mm sheath.

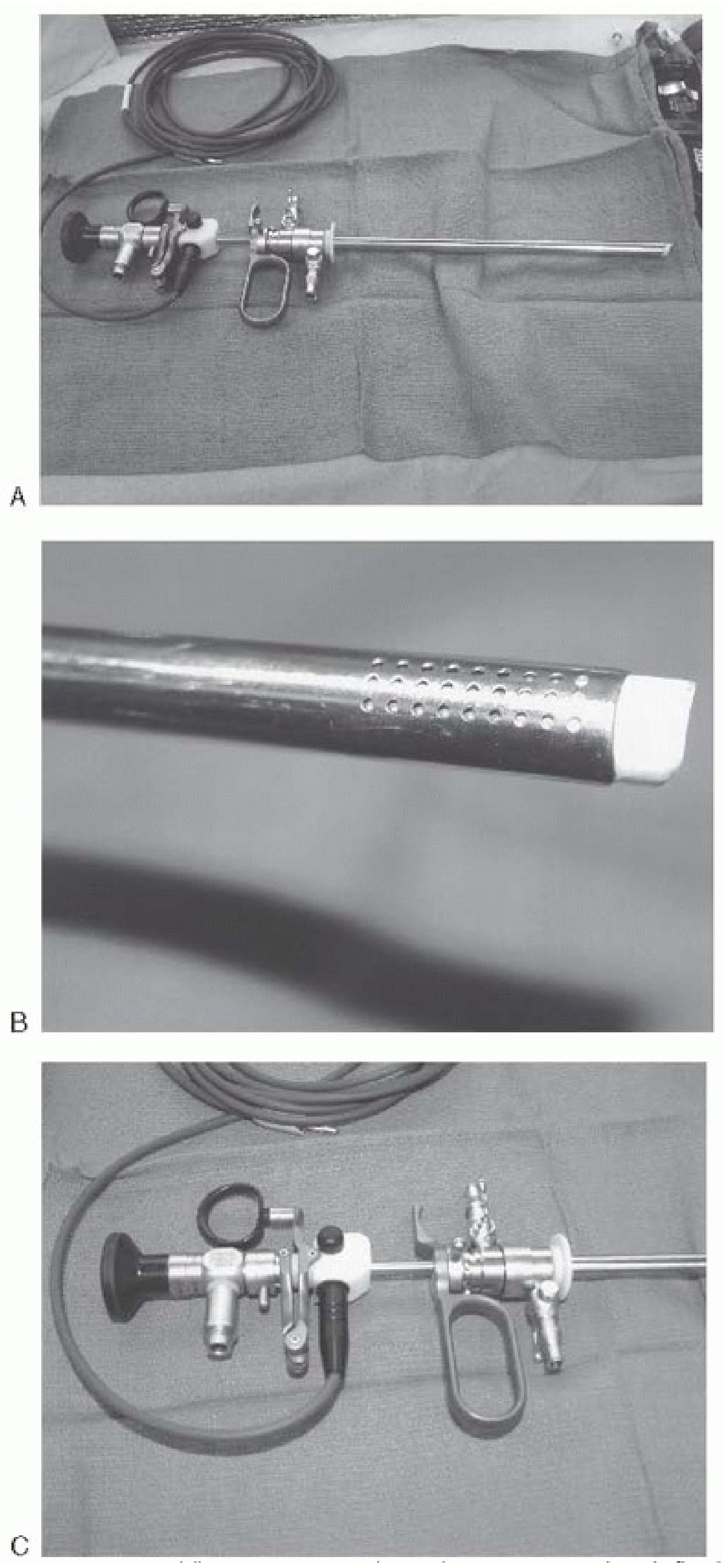

FIGURE 18.5 A: The resectoscope shown here is equipped with fluid entry and exit ports. A flushing sheath as the trigger mechanism is pulled back the electrode extends out from the terminal portion of the sheath. **B:** The terminal portion of the sheath shows the output external sheath. Fluid enters through the inner sheath (terminus white). **C:** A 30-degree telescope couples to the sheath. The electric cord carries current, which is transmitted to the electrode.

FIGURE 18.5 (*Continued*) **D:** The cutting loop electrode is the instrument for shaving submucous myomas. **E:** The ball or barrel electrode is the instrument most utilized for endometrial ablation. **F:** The button electrode is specifically employed to point coagulation. **G:** The angulated needle electrode is favored for fine cutting, for example, adhesions or pedunculated myomas.

CAMERA

In most cases today, hysteroscopy employs the endoscopic microchip camera coupled directly to the telescope, with digital cameras and digital recorders. Endoscopic video camera lenses range in focal length from 25 to 38 mm. A 28- to 30-mm lens provides satisfactory magnification. The view with the coupled camera provides magnification comparable to that obtained during microsurgery. If a video recorder is available, a permanent record of the procedure can be recorded. A xenon light generator provides the best illumination for video techniques, although less expensive light sources may be satisfactory when coupled to newer cameras, which are highly light sensitive.

ACCESSORY INSTRUMENTS

The standard accessories are the 7-F (i.e., 2.3-mm) alligator grasping forceps, biopsy forceps, and scissors. The small size of these semirigid instruments makes them particularly fragile, as excessive torque at the junction of the shaft and handle frequently leads to breakage. Flexible devices are less likely to fracture and are equally as facile compared with the semirigid variety. Development of the large isolatedchannel sheath has made the use of totally flexible 3-mm operating instruments feasible. The scissors and graspers are substantially heavier and much less prone to breakage (**Fig. 18.6A-D**).

A variety of monopolar and bipolar electrodes are also now available for operative hysteroscopy. Monopolar balls, needles, shaving loops (3 mm), and ridged (vaporizing) loops can be inserted through the large operating channel. Bipolar needles for myolysis, as well as bipolar ball and cutting loop electrodes, have been manufactured (**Fig. 18.7**), together with bipolar scissors and needles. The hysteroscopic sheath has an advantage over the resectoscopic sheath, allowing insertion of an aspirating cannula (2.3 or 3 mm), which permits the operator to selectively clear the field of bubbles and debris that cannot be removed by the way of the return second sheath. Nevertheless, the resectoscope is generally easier to use for the average gynecologist.

A complete bipolar system marketed under the trade name of Versapoint (Gynecare, Ethicon, Somerville, NJ) permits cutting and ablation via operative hysteroscopes or via a dedicated bipolar resectoscope. The mechanism for the bipolar current flow through the electrode is illustrated in **Figure 18.8A.** The electrodes measure 5-F diameter (i.e., 2 mm) and therefore can be accommodated by standard and isolated hysteroscopic channels (**Fig. 18.8B**). The biggest advantage of this bipolar technology is that saline may be used as the distending medium for the operative hysteroscopy. This obviates the risk of hyponatremia (see sections on media and complications). Hysteroscopic morcellators have also been developed as an alternative to the resectoscope in removing uterine submucosal myomas. Two such systems are TRUCLEAR hysteroscopic morcellator (Smith & Nephew, Andover, MA) and the MyoSure tissue removal system (Hologic, Bedford, MA) (**Fig. 18.9A**, **B**). Both systems use suction-based, mechanical energy, rotating tubular cutter systems rather than the highfrequency electrical energy used by resectoscopes. The benefits of these systems include the ability to use isotonic distension media such as normal saline and an improved visual field as resected “fibroid chips” are removed.

The Flexible Hysteroscope

The 4.8-mm-diameter fiberoptic hysteroscope consists of three sections: a soft flexible front section, a rigid rotating middle section, and a semirigid rear section. In 1990, Lin

and colleagues reported their experiences with this instrument in 153 procedures, including transcervical tubocornual recanalization, chorionic villus sampling, and retrieval of lost intrauterine devices (IUDs). The flexible hysteroscope has particular advantage in its ease of aligning the catheter for tubal canalization. Several manufacturers now produce fiberoptic (flexible hysteroscopes) (**Fig. 18.10**). Contemporary fiberoptic hysteroscopes are available with single-use, sterile sheaths that eliminate need to sterilize equipment between cases.

FIGURE 18.6 A: Direct vision intrauterine biopsies may be performed utilizing the biopsy forceps. **B:** Crocodile-jawed forceps are ideal for grabbing and retaining devices or tissue within the uterine cavity. **C:** Scissors have a variety of intrauterine applications, including cutting adhesions and uterine septa. **D:** Tenaculum allows a puncturing grasp that is more secure than that of the crocodile-jawed forceps.



FIGURE 18.7 A: This straight cutting needle (insulated with Teflon) protrudes from the terminal portion of the sheath of a flushing operating hysteroscopy. This device can cut septa, adhesions, myomas, and polyps. **B:** The button electrode may be inserted through the operating channel and used for coagulation indications but never for cutting. **C:** A 3-mm bipolar needle that can be inserted into a submucous myoma for myolysis.



FIGURE 18.8 A: The mechanism of action for the Versapoint bipolar electrode is illustrated. The coiled bottom portion is the active electrode, and the upper (separately illustrated) metal portion serves as the return electrode. The saline medium facilitates the conduction of current between the two poles. **B:** Several bipolar electrodes are shown. The major advantage of bipolar devices is the ability to use normal saline as the distending fluid medium.

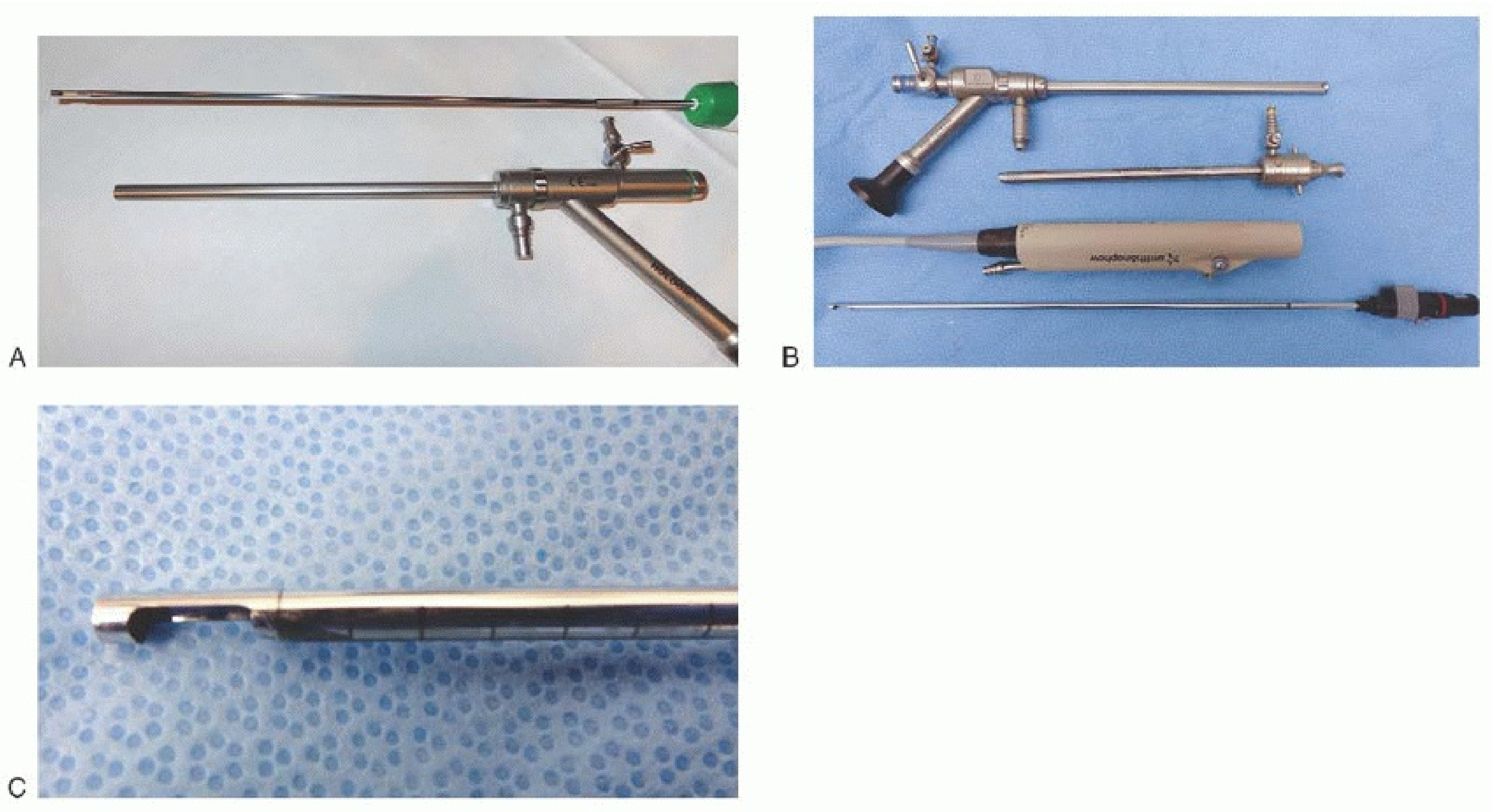

FIGURE 18.9 A: Hysteroscopic morcellator setup by Hologic. Note the angled telescopic portion, which allows the camera to be attached. Disposable device is inserted down an operative channel. **B:** Hysteroscopic morcellator setup by MyoSure. From top down is the angled telescope with an operative channel and media inflow port. The outer sheath includes an articulated obturator that allows for a blind entry if preferred by the surgeon. The motor attaches to suction and the below disposable morcellating piece. **C:** The working/cutting end of the morcellator. Note the blunt end with a protected rotating blade located inside the curvature, which oscillates cutting tissue and pulling cut portions inside the lumen of the instrument for removal. Cutting can only occur along the lateral open edge.

DISTENDING MEDIA

Under normal circumstances, the uterine cavity is a potential space, with the anterior and posterior walls in close apposition. To achieve a panoramic view within the uterus, the walls must be separated. The thick muscle of the uterine wall requires a minimum pressure of 40 mm Hg to distend the cavity sufficiently to see with a hysteroscope. Because the endometrium is richly endowed with blood vessels, touching it with the sheath of the hysteroscope often produces bleeding. Although a variety of distending media can be used to attain the desired degree of distention, it usually requires pressures approximating 70 mm Hg, which at the same time propels the medium through the oviducts into the peritoneal cavity. Overdilatation of the cervix with a loosely applied hysteroscopic sheath results in leakage of the medium, suboptimal pressure, and poor expansion of the uterine cavity. In contrast, a tight application of the sheath maintains the medium within the cavity, keeps intrauterine pressure above mean arterial pressure, and maintains a clear operative field.

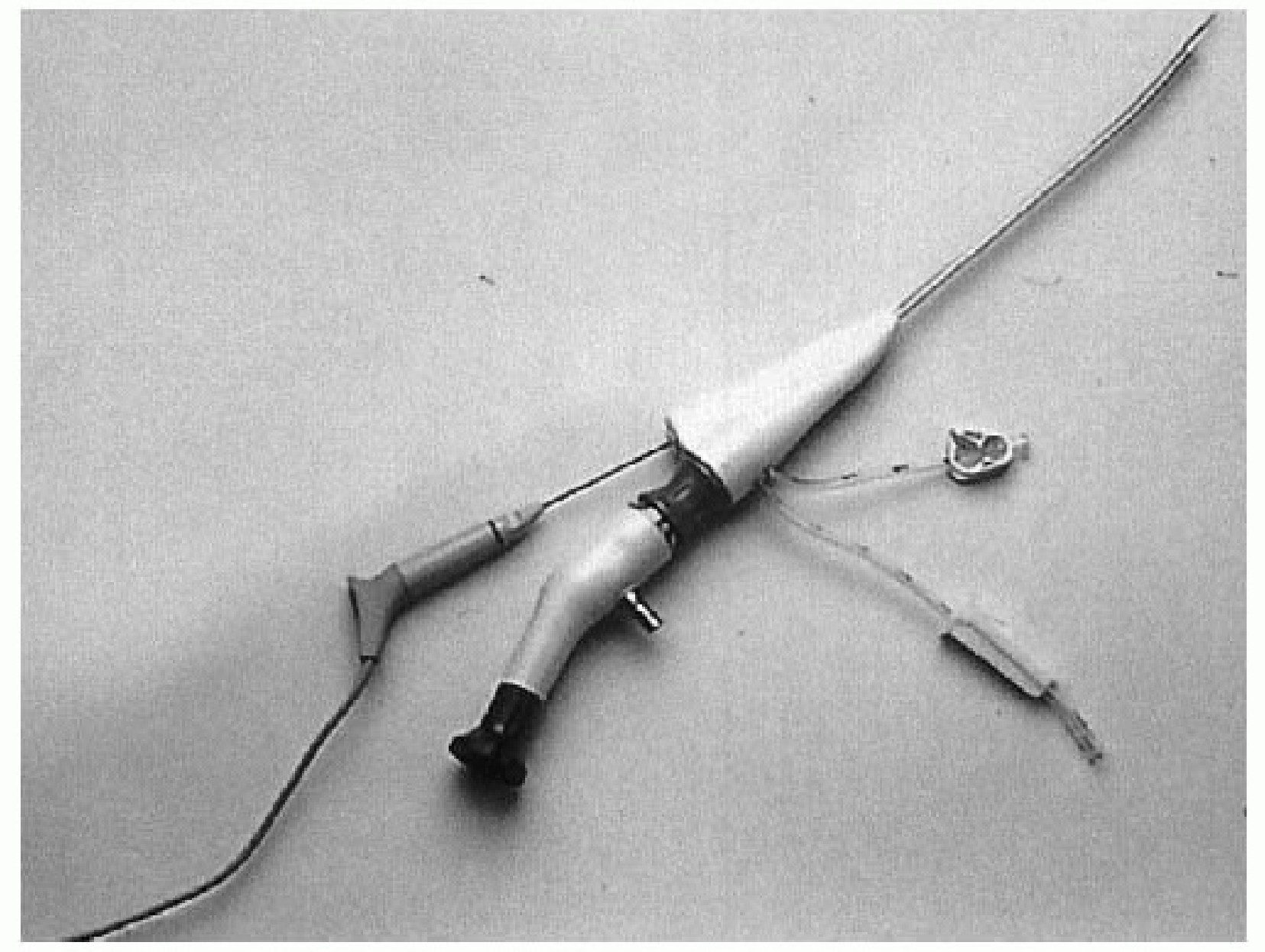

FIGURE 18.10 Flexible fiberoptic hysteroscopes can be manipulated to turn at virtually any angle.

Media can be conveniently divided into gaseous or liquid. The latter may be further subdivided into high-viscosity and low-viscosity fluids.

GASEOUS MEDIA

Carbon Dioxide

CO_2 is a colorless gas that is highly soluble when mixed with blood. It can be used to safely distend the uterus when instilled with a proper insufflation apparatus. CO_2 is ideal for diagnostic hysteroscopy. The hysteroscopic insufflator (**Fig. 18.11**) delivers CO_2 into the uterus at a flow rate measured in cubic centimeters per minute, in contrast to the laparoscopic insufflator, which allows CO_2 to flow in at a rate of liters per minute. The laparoscopic insufflator is both unsuitable and unsafe for hysteroscopic insufflation. The rate of flow of CO_2 into the uterus should never exceed 100 mL per minute, and pressure should be adjusted below 150 mm Hg. Before CO_2 is infused, the hysteroscopic tubing and the hysteroscope must be purged of air. Additionally, the Trendelenburg position should be avoided.

When CO_2 flow is excessive, bubbles appear and obscure the field. CO_2 tends to flatten the endometrium, and this artifact can obscure pathology. When CO_2 is improperly instilled, emboli form and can produce severe derangements in cardiovascular physiology. Advantages of CO_2 as a distention medium include its neatness. It does not foul instruments, it does not mess up the office or operating room, and it allows entry evaluation of the endocervical canal. CO_2 is therefore an excellent diagnostic medium. The disadvantage of CO_2 is that it cannot be used for operative hysteroscopy due to risk of CO_2 embolism.

FIGURE 18.11 CO_2 is infused using a specific hysteroscopic insufflator that measures the flow rate (100 mL per minute) and uterine pressure (not to exceed 150 mm Hg). Laparoscopic CO_2 insufflation devices cannot be used for hysteroscopy due to a much higher flow rate designed to expand the abdominal cavity.

LIQUID MEDIA

High Viscosity

Hyskon (32% dextran 70 in dextrose) is a colorless, viscid solution that is rarely used today for diagnostic and operative hysteroscopy. An advantage of Hyskon is its immiscibility with blood, which permits excellent visualization, even during active bleeding. A disadvantage of Hyskon is that dried residue tends to harden and clog hysteroscopic sheath channels. Two types of severe patient reactions unique to Hyskon have been reported: a syncratic anaphylactoid reaction and a bleeding diathesis. The hematologic reaction is caused by excessive vascular uptake of dextran, which allows a more general manifestation of its physiologic actions, including fibrinoplastic action, stearic exclusion, alteration of platelet adhesiveness, and interference with von Willebrand factor (factor VIIIR). Hyskon also places a patient at risk for fluid overload. The osmotic activity of dextran is such that for each gram of Hyskon instilled into the vascular space, 20 mL of interstitial water will be pulled into the circulation; 100 mL of Hyskon (32% dextran) will expand the plasma volume by 32 g × 20 mL, or a total of 640 mL. As the volume of intravascular Hyskon increases, a critical level is reached, and pulmonary edema occurs. Finally, dextran 70 (Hyskon) is a mixture of macromolecules ranging from 25 to 125 kd. Although the lower-weight molecules are rapidly excreted, the larger molecules can interfere with glomerular filtration and will remain in the bloodstream for 4 to 6 weeks.

Low Viscosity

Low-viscosity fluids must be continuously flushed through the uterine cavity if a clear view is to be obtained. Delivered fluid must be continuously circulated out of the cavity and clean fluid constantly added to make up for the deficit and maintain uterine distension. A standard diagnostic sheath does *not* allow for flushing. Therefore, if a low-viscosity fluid is used for distension, the view may be suboptimal because blood can mix with the distending fluid, creating a colored fluid through which the operator will see the field. The safest distending medium will be isoosmolar—that is, the electrolyte content will amount to 300 mOsm. Additionally, the sodium content of the fluid should approximate 140 mEq/L. The ideal lowviscosity fluid medium is 0.9% sodium chloride.

Regardless of the type of medium infused, the surgeon is responsible for monitoring the infused volume and reconciling that volume with the collected volume. Positive infusion differences require that the procedure be stopped when deficits range from 500 mL (for hypoosmolar fluids) to 1,000 mL (isoosmolar fluids). The surgeon and anesthesiologist must communicate, because fluid overload scenarios will usually necessitate the anesthesiologist helping to manage the ensuing pathophysiology. Additionally, intravenous fluids infused by the anesthesia team will add to the increased circulatory volume. Finally, any fluid including physiologic salt solutions can produce pulmonary edema when excessive volumes are administered via the hysteroscope, because the pressure gradient to maintain uterine distension is 60 to 70 mm Hg and subendometrial venous pressure is 4 mm Hg. Inevitably, fluids will diffuse into the venous circulation.

Low-viscosity distention media may be delivered by hanging a 2- to 3-L bag or bottle of fluid 6 to 8 feet above the operating table, permitting the fluid to infuse by gravity feed (**Fig. 18.12A**). An alternative is instilling low-viscosity fluid by rotary pump (**Fig. 18.12B**). The newest pumps weigh the fluid in real time and give the surgeon a constant readout of flow rate and total volume of fluid infused (**Fig. 18.12C**, **D**). Use of an automated fluid pump and monitoring system is advocated by both the American Congress of Obstetricians and Gynecologists and the American Association of Gynecologic Laparoscopists to most accurately monitor inflow and outflow and prevent complications associated with fluid overload.

Normal Saline, Ringer Lactate

Normal (physiologic) saline (0.9% sodium chloride) is perhaps the safest of any hysteroscopic media. Complications of excessive vascular absorption include fluid overload and pulmonary edema, which are managed by diuresis and support. The medium is readily available in 3-L sterile bags that can be mounted on an intravenous pole or given via an infusion pump. Garry and colleagues (1992) reported excellent safety results and precise maintenance of uterine pressure by using a pump delivery system, which was combined with one of the operating channels of the dual-channel operating sheath to provide an outflow tract and thus a constant flow rate through the uterine cavity.

Unfortunately, because saline is an efficient conductor of electrons, it does not permit a current density that is high enough for tissue action when using a monopolar system. Saline is therefore not suitable for monopolar electrosurgery, although it is effective when the Nd:YAG laser, the KTP/532 laser, bipolar electrode, and mechanical devices such as scissors are the hysteroscopic accessories of choice.

The optimal drape for the operating room is the urologic pouch (tucked under the buttocks) with a plastic reservoir pocket into which the outflow fluid may be collected and quantified to determine the fluid deficit (the difference between instilled fluid and returned fluid). The surgeon should be given a running account by a nurse or surgical assistant of the volume of fluid instilled, which is calculated as the liters of fluid hung minus volume of return fluid. Whenever any significant fluid deficit is calculated, usually considered 2.5 L for isotonic saline, the procedure should be discontinued and scheduled for completion at a later date.

Glycine 1.5% and Sorbitol 3%

Glycine (1.5%) and sorbitol (3%) solutions were first used in urologic surgery, principally for male patients. They were adopted later by gynecologists for use with monopolar electrosurgical devices such as the resectoscope. Both glycine and sorbitol are used for hysteroscopic distension, but both have disadvantages inherent to their composition. Since these solutions are hypoosmolar (sorbitol, 178 mOsm/L; glycine, 200 mOsm/L), the principal hazard relates to their vascular absorption and the creation of an acute hyponatremic, hypoosmolar state. A fluid deficit equal to or greater than 750 mL should alert the surgeon to a likelihood of hyponatremia and hypoosmolality. Two reports have presented data concerning significant complications secondary to hyponatremia. In one series of four women, two died (50% mortality); in the other, one of four women died (25% mortality). Absorption of hypoosmolar solutions produces a gradient between the circulating blood and the brain cells. The brain cells respond by pumping cation out to diminish the positive infusion of water into the brain. Unfortunately, the cation pumping mechanism of the brain is deficient in women, secondary probably to the actions of progesterone, and women are at significantly greater risk for the development of life-threatening cerebral edema when a hypoosmolar state exists. At a minimum, intraoperative and 4-hour postoperative serum sodium levels should be requested on a stat basis if concern for a fluid deficit using a hypoosmolar medium exists. A unique disadvantage of glycine is that it can be metabolized to ammonia and cause neurologic damage.



FIGURE 18.12 A: This fluid instillation system is suspended from the ceiling and is equipped to handle four 3-L bottles or bags. The height is easily adjusted to provide a head of pressure to infuse into the uterus. **B:** The advantage of this pump relates to its ability to provide a constant flow of low-viscosity fluid and to maintain sufficient pressure to keep the uterine walls distended. **C:** This pump delivery system not only delivers fluid but also weighs each bag and continuously calculates fluid volume infused and volume collected. **D:** This apparatus is very similar to the technology shown in part **(C)**, but permits the usage of multiple bags of fluid.

5% Mannitol and 2.2% Glycine

Mannitol (5%) and glycine (2.2%) may be used with electrosurgical devices and are approximately isoosmolar. Mannitol has an osmolality of 285 mOsm and is an osmotic diuretic. Its optical characteristics are equivalent to glycine and sorbitol; however, it is a safer medium. In a study of 181 hysteroscopic examinations using isotonic

2.2% glycine, although there was a mean decrease in sodium of 9 mmol/L in patients absorbing 1,000 mL, the serum osmolality remained normal with no significant adverse sequelae.

DIAGNOSTIC HYSTEROSCOPY TECHNIQUES

Diagnostic hysteroscopy can be performed in an office setting under local anesthesia. The injection of lidocaine 1%, 10 to 15 mL, directly into the cervix produces adequate anesthesia. Discomfort for the patient can be further diminished by ibuprofen (Motrin), 600 to 800 mg, administered 30 minutes before the procedure. Patients who require cardiac prophylaxis (e.g., artificial heart valves) should be covered by appropriate antibiotics. Informed consent clearly reviewing the risks, benefits, and alternatives should be obtained.

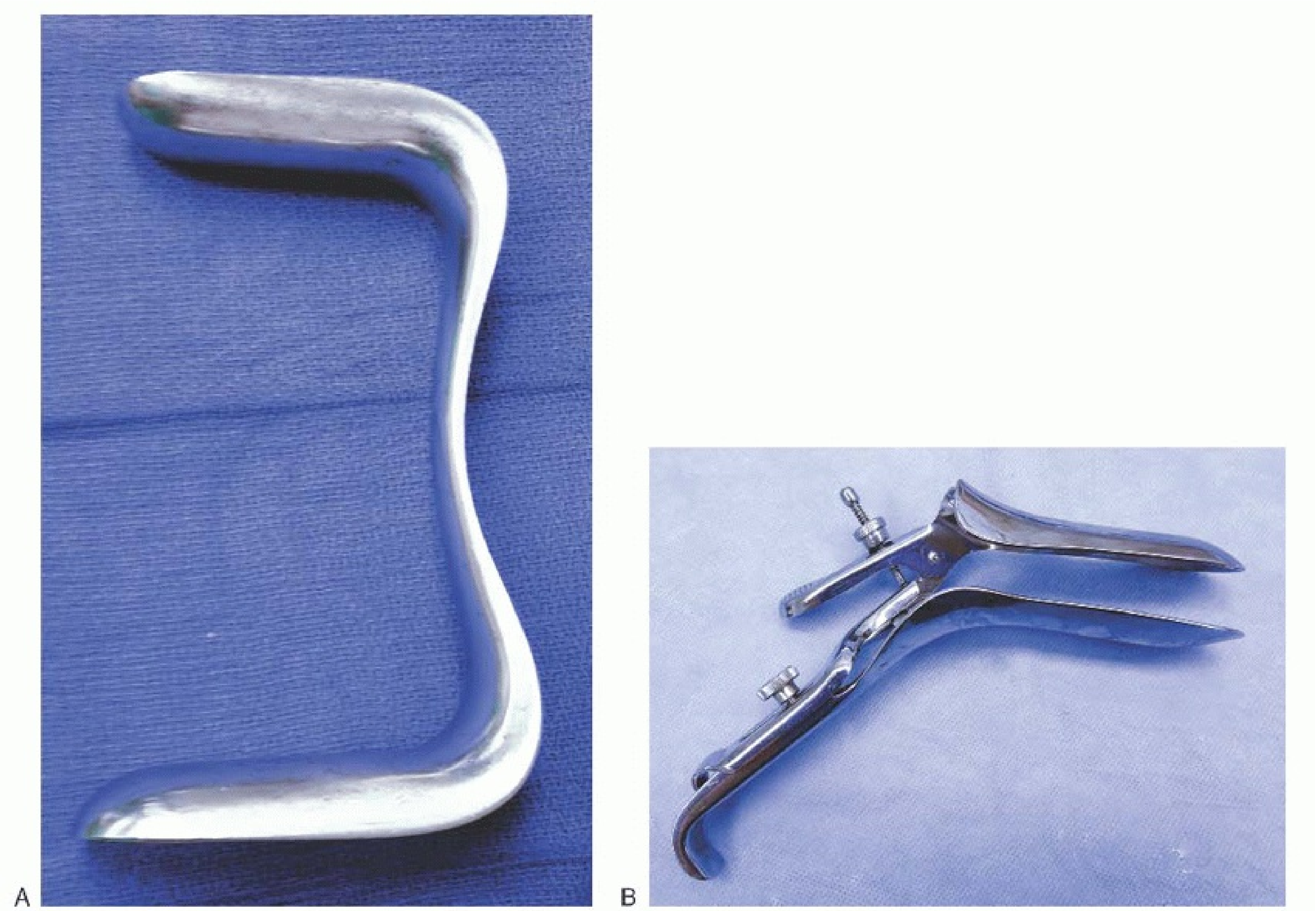

FIGURE 18.13 A: The Sims retractor is excellent for retracting the posterior vaginal wall and is easily removed following placement of the hysteroscope. **B:** Bivalve speculum can be used with similar results as the Sims retractor and is ideal for use in the absence of an assistant. The speculum or Sims retractor should be removed once the hysteroscope is positioned in the external cervical os to allow full mobility with a direct entry technique.

Accurate knowledge of the position of the uterus is critical to safely facilitate the procedure. The optimal view of the uterus is obtained during the proliferative phase of the menstrual cycle. After placing the patient in the dorsal lithotomy position, the perineum and vagina are gently swabbed with Betadine or another suitable antiseptic solution. A Sims retractor or breakaway speculum is inserted to allow visualization of the cervix (Fig. 18.13). The edge of the cervix at the 12 o'clock position is grasped with a single-toothed tenaculum. A suitable telescope is selected and checked by the operator for clarity of the eyepiece and objective lens. If necessary, the lens is cleansed with a soft saline-soaked or water-soaked sponge. The light generator is switched on, and the fiberoptic cable is attached to the telescope. The telescope is inserted into the diagnostic sheath, and the selected medium is flushed through the sheath to expel any air within the sheath (Fig. 18.14A, **B**).

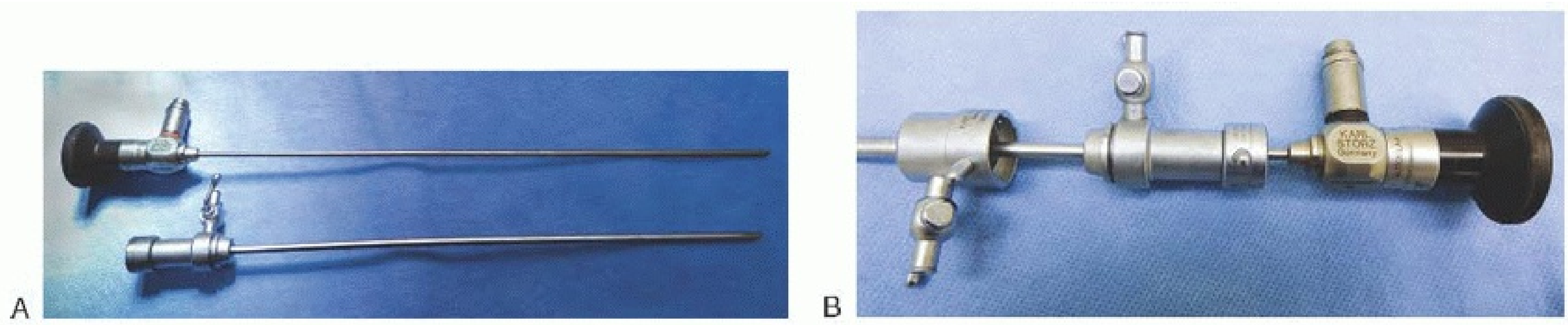

FIGURE 18.14 A: The diagnostic lens (telescope) and its 5-mm inner diagnostic sheath are excellent instruments for office or surgicenter outpatient hysteroscopy. **B:** Close-up showing 4-mm telescope engaging into both the inner and outer diagnostic sheaths (note: the locking pins are still in the open position).

If CO_2 is the selected medium, the flow rate is adjusted to deliver 30 mL per minute. The hysteroscope is engaged into the external cervical os. As the endoscope is advanced, the gas separates the walls of the endocervix, allowing an excellent view of the endocervical folds and crypts. The internal os is seen above as the endoscope is manipulated along the axis of the canal and through the os under direct vision (**Fig. 18.15A, B**). Flow is adjusted to a rate 60 mL per minute when the isthmus is entered.

Routine dilatation of the cervix should be avoided, because even gentle insertion of cervical dilators can traumatize the endocervix and endometrium. Typically, the endocervical canal shows longitudinal folds, papillae, and clefts. The internal os appears as a narrow constriction at the top of the endocervical canal. The isthmus is a cylindrical extension above the os. The corpus is a capacious cavity above the isthmus. The central point of müllerian duct fusion is seen projecting down from the fundus. The cornua occupy either side of this fused area. The tubal ostia are visible at the upper extremities of the fundal cornua and show great variation in their appearance and angle of entry into the uterine cavity. The uterine endometrium is smooth and pink-white in color during the proliferative phase. The gland openings appear as white-ringed elevations surrounded with netlike vessels. During the secretory phase of the cycle, the endometrium is lush and velvety; it protrudes into the cavity irregularly and can be easily mistaken for small polyps. The hue of secretory endometrium is magenta. When CO_2 is the distending medium, the endometrium is artificially flattened. Although the cornua are easily recognized, the tubal ostia may not be seen during the latter phase of the menstrual cycle.

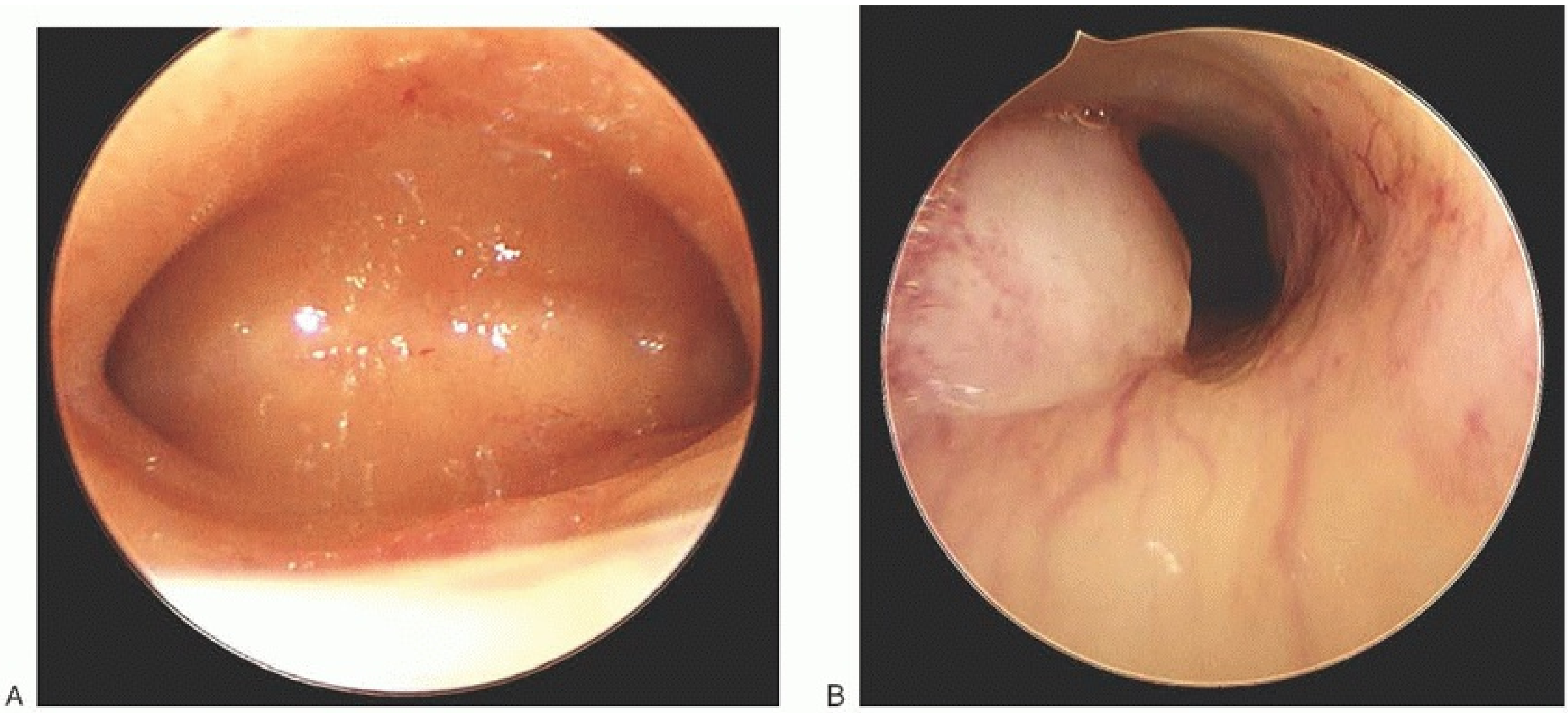

FIGURE 18.15 A: Hysteroscopic image using CO_2 to distend the intrauterine cavity. The hysteroscope's objective lens is just above the internal os allowing a panoramic view of the cavity. The recesses to the right and left are the cornu. **B:** This view is taken within the distended cervix looking upward into the dark corpus. Note a

paracervical polyp along the lateral edge.

OPERATIVE HYSTEROSCOPY TECHNIQUES

To begin, the telescope is inserted into the operative or resectoscope sheath. If the operative sheath is used, a proper nipple is selected and attached to the opening of the operating channel (Fig. 18.16A, B). The sheath is flushed with the distending medium, and the light cable is attached. Careful dilatation with Pratt dilators should be performed until the operative sheath negotiates a tight passage through the cervix. With the medium flowing, the hysteroscope can be inserted into

the uterine cavity under visualization. The uterine cavity is scanned, and the operator mentally notes landmarks (e.g., the tubal ostia, depth of the cornua, the location and attachments of the lesion, the proximity of the internal cervical os). The flow of the debris with the liquid medium will also help the operator locate the tubal ostia. If there is difficulty viewing the cavity clearly, the hysteroscope has probably been inserted too deeply, and the telescope has come in contact with the uterine wall. When the view is blocked, the most prudent first maneuver is to pull the instrument back with the medium flowing into the uterus.

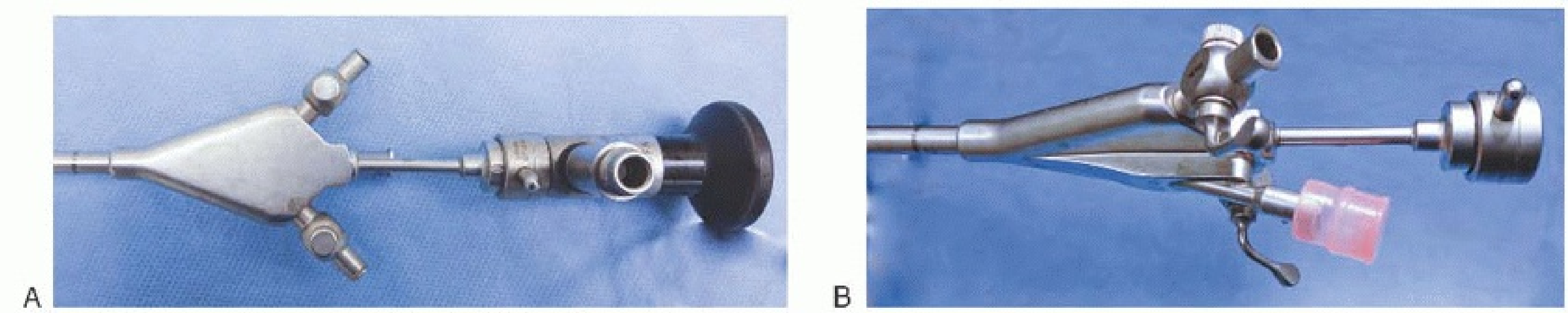

FIGURE 18.16 A: The telescope is secured by means of a watertight pin and screw mechanism. **B:** Close-up of operating sheath. A pink-colored nipple cover is attached to the operating channel, which allows passage of the instrument without backflow of distention media. The two stopcocks are for infusion of the distending medium and return and jettison of circulating fluid. Note all stopcocks are opened.

After a clear view is obtained, the operating device (e.g., electrode or scissors) is inserted into the cavity and advanced to make contact with the endometrium for relative calibration and spatial orientation within the cavity. The cavity can also be further distended with a constant flow sheath by closing off the return valve stopcock. The valve is then opened, and the cavity is flushed clear.

In certain cases, it is advantageous to perform a simultaneous laparoscopy to permit an assistant to view the serosal surface of the uterus to provide some additional insurance against inadvertent perforation. Clinical scenarios in which simultaneous laparoscopy may be beneficial include excision of a septum, lysis of uterine adhesions, and excisions of large submucous myomas.

ELECTROSURGICAL DEVICES AND LASERS

Electrosurgical devices and lasers both exert their tissue actions in a similar fashion. Light energy from lasers is transformed to thermal energy by electron flow. Lasers and electrosurgical devices both produce coagulation at 60 to 70°C and vaporization at 100°C (Table 18.1), and both require sufficient power density to exert the desired action. Similar tissue actions can be produced by raising the power density or by keeping the power constant and increasing the tissue exposure time. A 1-mm laser fiber delivering 30 watts (W) of power to tissue will create a power density of 3,000 W/cm^2. A 3-mm ball electrode will need to generate 300 W of power to create a similar power density. The Nd:YAG laser, which works by thermal energy, is the preferred laser for hysteroscopic surgery. The Nd:YAG laser beam can be transmitted equally well with any distending medium, whereas monopolar electrosurgical devices operate most effectively in an electrolyte-free medium.

The surgeon must be familiar with the physics governing the actions of electrosurgical tools and lasers and with the tissue actions exerted by these energized devices. A knowledgeable surgeon would not use a ball device to cut or a loop electrode to coagulate tissue. Proper selection of wattage depends on disease pathology and location. High power applied for a long period of time is risky and puts the patent at risk for tissue injury.

Regardless of whether a resectoscope, handheld electrode, or laser is used, depth of tissue action is extremely important. Transmural injury is possible at high-power densities or with prolonged exposure. One must keep in mind that the thickness of the distended uterine wall (0.5 to 1 cm) is considerably less than that of the nondistended uterine wall (1.5 to 2 cm) (**Fig. 18.17A, B**). Uterine perforation by either a laser fiber or an electrode is much more serious than perforation by scissors or another mechanical device, because the thermal energy can inflict great damage to surrounding structures (e.g., bowel or bladder). The injury may not attain its maximum damage until 2 or 3 days after surgery. Therefore, either laparoscopy or laparotomy is indicated in such cases to determine the extent of injury.

TABLE 18.1 Gross Effects of Thermal Injury as Caused by Both Laser and Electrosurgery Apparatus

APPROXIMATE DEGREE OF HEAT	THERMAL DAMAGE CAUSED
<40°C	No significant cell damage.
>40°C	Reversible cell damage, depending on the duration of exposure.[a]
>49°C	Irreversible cell damage (denaturation).[a]
>70°C	Coagulation (Latin: coagulation 5 clotting). Collagens are converted to glucose.
>100°C	Phase transition from liquid to vapor of the intracellular and extracellular water. Tissue rapidly dries out (desiccation) (Latin: ex sico 5 dehydration). Glucose has an adhesive effect after dehydration.
>200°C	Carbonization (Latin: *carbo* 5 coal). Medical pathologic burns of the fourth degree.

[a] According to Bender and Schramm (1968).

FIGURE 18.17 A: A uterus that is removed at hysterectomy shows the thick walls of the myometrium. These walls average approximately 1.5 cm in thickness, with the exception of the cornu, where the myometrium is thinner. **B:** The uterus is distended with the liquid medium. The walls of the uterus are now much thinner, averaging 0.5 to 1 cm in thickness.

SPECIFIC PROCEDURES IN HYSTEROSCOPIC SURGERY

Septate Uterus

Modern hysteroscopy has rendered the correction of the septate uterus relatively simple and straightforward by the transcervical route. Uterine septae are a treatable factor contributing to pregnancy wastage usually secondary to spontaneous abortion. The diagnosis of a uterine septum is usually made after a hysterosalpingogram or during a diagnostic hysteroscopy. Unfortunately, neither of the studies mentioned above differentiates between septate and bicornuate uteri. Historically, a diagnostic laparoscopy has been most helpful for an accurate differential diagnosis. A laparoscopic view of a septate uterus will reveal a wide but otherwise normal fundus, whereas the bicornuate uterus typically appears heart shaped. More recently, **MRI** of the pelvic has emerged as an imaging modality that in most cases can differentiate between a septate and bicornuate uterus. A bicornuate uterus, if pregnancy wastage is demonstrated, should be treated by a Jones or Strassman procedure. A septate uterus should be treated hysteroscopically. The standard technique, first reported in 1978 by March and colleagues, is to cut the septum with scissors under direct hysteroscopic view.

Cararach and colleagues compared hysteroscopic incision of septate uteri during a 5-year period (81 women) using a scissors or resectoscope approach and found only marginal benefit in favor of the former. Choe and Baggish used the Nd:YAG laser fiber to transect septa in 14 women. Of 13 patients who conceived, 10 delivered a live-born, term infant (87%), compared with a preoperative term pregnancy rate of 11%. Laser, resectoscope, or needle electrodes are more appropriate for the broad and usually vascular septum. Four recent studies by Litta et al., Pabuccu and Gomel, Saygili-Yilmaz, and Patton and Novy evaluated reproductive outcomes following hysteroscopic metroplasty. The percentage of pregnancies reaching term following metroplasty ranged from 50% to 83%.

Uterine rupture during pregnancy and more specifically in labor has been reported after hysteroscopic metroplasty with or without uterine perforation. It would therefore be prudent to inform the patient who will undergo metroplasty of the subsequent risk, so that she is knowledgeable and can inform her obstetrician should she become pregnant.

Hysteroscopic Technique

The uterine septum is viewed from the level of the internal cervical os. The endoscope is moved into each chamber of the divided uterine cavity, and the locations of the tubal ostia are noted. The hysteroscope is again withdrawn to a level just above the internal os. The appropriate operating instrument is inserted through the sheath, and the septum is divided in its midportion (**Figs. 18.18** and **18.19**). There is usually no need to remove tissue, as the septal tissue retracts after it is incised. In many cases, it is beneficial to perform simultaneous laparoscopy. As the fundus is approached, the operator depends on a signal from the assistant performing the laparoscopy to indicate when the quality of the hysteroscope light demonstrates transmission through the intact uterine wall. A dialog between the hysteroscopist and laparoscopist prevents perforation. A newer technique permits the operator to scan the uterus ultrasonographically to

determine whether the myometrium has been entered and to monitor the amount of space existing between the operating device and the serosal surface of the uterus. The surgeon should be aware of the common tendency of the cutting instrument to drift posteriorly and should clip the septum squarely in the middle. When the drift goes unnoticed, the operating instrument can cut into the myometrium and cause pulsatile bleeding. Similarly, correcting the septum too perfectly at the level of the fundus will result in deep penetration into the myometrium and subsequent hemorrhage. If a multichannel hysteroscope is used, a 3-mm ball electrode may be used to coagulate the bleeding vessel. The double-needle bipolar electrode is a safe alternative method for electrocoagulation.

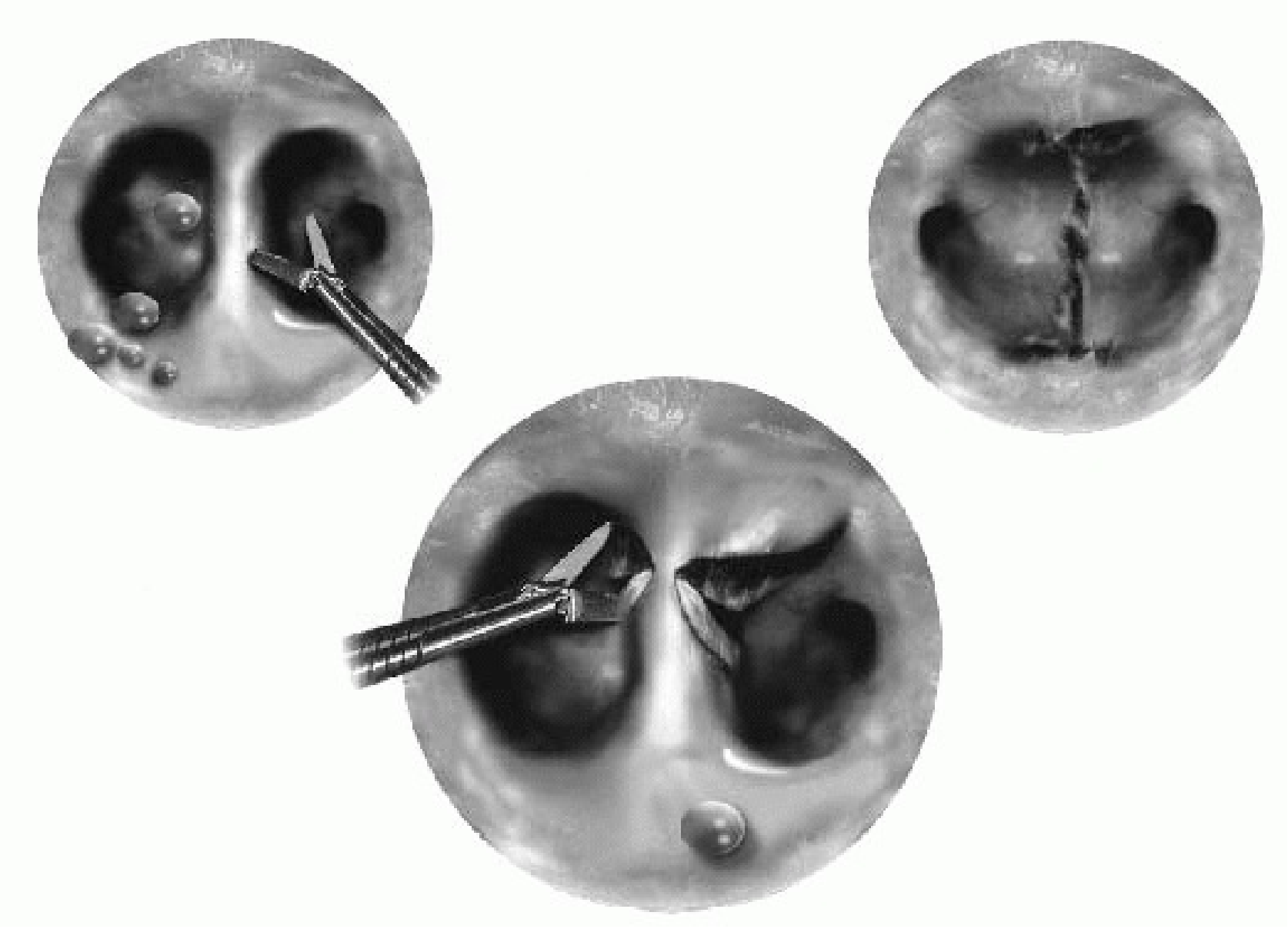

FIGURE 18.18 *Upper left:* Hysteroscopic view of a septate uterus immediately before cutting the septum. *Center:* The septum is cut approximately at midpoint, taking care not to drift too far posteriorly. Thicker septa are cut from periphery inward to the center. *Upper right:* The septum has been completely incised. (Reprinted with permission from Baggish MS, Valle RF, Guedj H. *Hysteroscopy: visual perspectives of uterine anatomy, physiology and pathology,* 3rd ed. Philadelphia, PA: Lippincott Williams & Wilkins, 2007, with permission.)

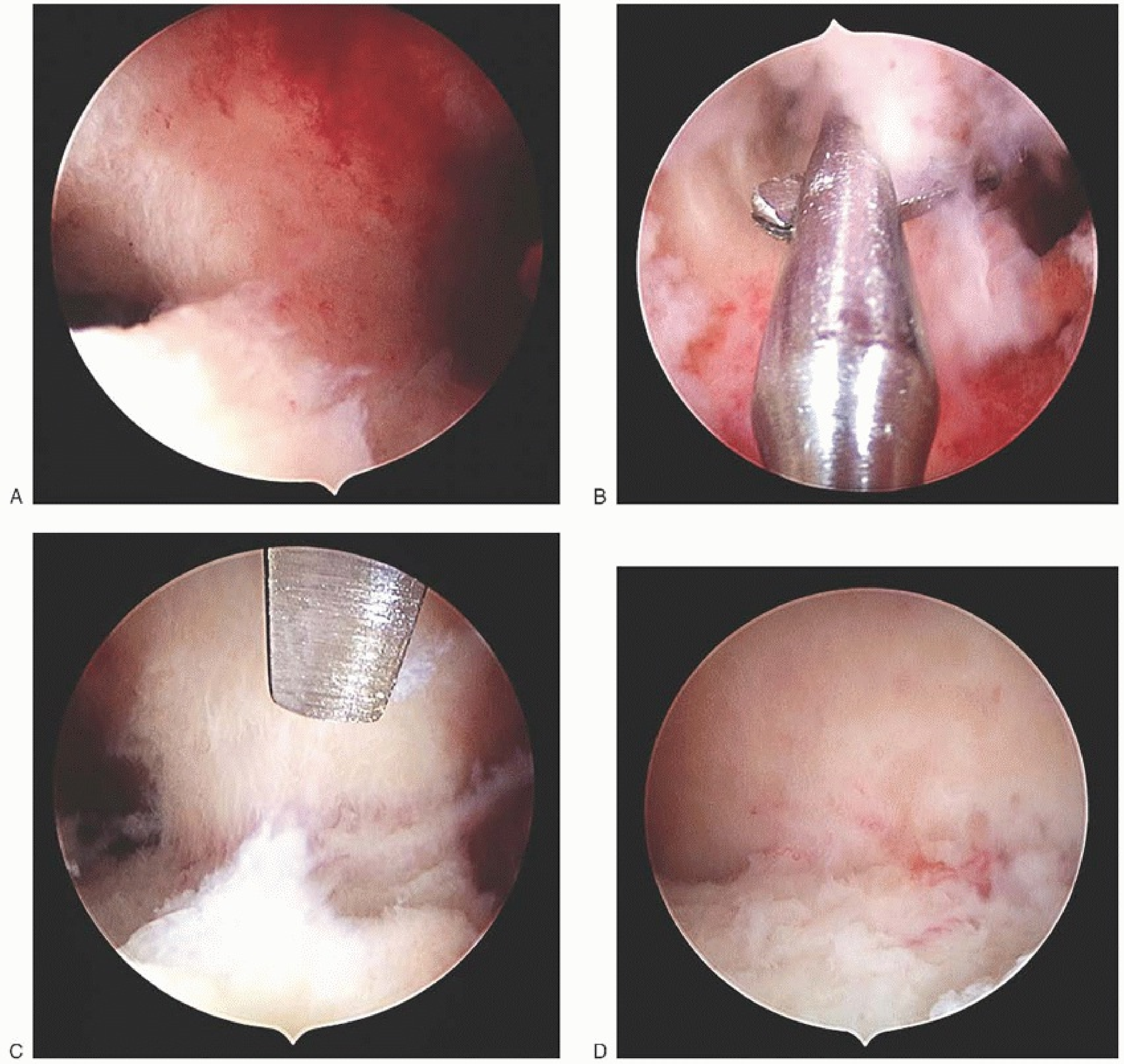

FIGURE 18.19 A: Hysteroscopic view of a septate uterus taken immediately before incising the septum. **B:** The septum is cut at its midpoint via hysteroscopic scissors. **C:** The central portion of the septum with the initial incision. **D:** Complete resection of the septum. Note the avascular and fibrous appearance of the septum, just lateral to the resection both cornea are congruent with the resection. (Photographs courtesy of Dr. Lauren Schwartz.)

If bleeding does ensue, a Foley catheter with a 10-mL balloon can be inserted into the endometrial cavity at the end of the procedure and inflated to 5 to 6 mL. The pressure exerted by the bag on the uterine walls is sufficient to control the bleeding promptly. The bag is deflated 6 to 12 hours postoperatively and is removed if no further bleeding ensues. Patients are usually advised to take conjugated estrogen daily following surgery. Antibiotics are not routinely administered.

Uterine Synechiae

Adhesions form between the anterior and posterior walls of the uterus as a result of trauma or infection in a milieu of estrogen deprivation. This condition is often referred to as Asherman syndrome. Classically, this problem follows an abortion or postpartum hemorrhage, for which a vigorous curettage has been performed to control the bleeding. Friedler and associates reported the incidence of adhesions after one abortion to be 16.3%. This figure rose to 32% after three or more abortions. The severity of adhesions also typically rises as the number of abortions increases. In most cases, the patient does not resume menstruation; however, a minority of patients continues to menstruate normally. Because the patient is subsequently infertile or amenorrheic, a hysterogram is performed. The radiograph reveals filling defects that vary from minimal to severe (i.e., virtually obliterating the endometrial cavity). Previous treatment of uterine synechiae consisted of blind curettage, and the results were predictably poor. With the advent of operative panoramic hysteroscopy, treatment progressed to identification of adhesions and sharp incision of the adhesions with scissors (**Fig. 18.20**).

Adhesiolysis surgery is probably the most difficult of hysteroscopic operations. Because numerous vascular channels are opened, the risk of intravascular absorption of the medium is high. Rock and colleagues reported a technique of laparoscopically injecting the uterus with leucomethylene blue dye to help identify the junction at which the anterior and posterior walls were adhered. Capella-Allouc and associates reported 31 cases of severe adhesions that underwent hysteroscopic lysis ranging over one to four operations. The number of subsequent pregnancies after treatment was 43%, and the live birth rate was 32%. A 2004 report from Belgium of 46 women with Asherman syndrome, of whom one third had severe adhesions, described live births as greater than 40%.

Hysteroscopic Technique

A thorough diagnostic hysteroscopy is performed to assess the degree of adhesion formation and deformity of the cavity. Small openings in the curtain of adhesions in which there are flow patterns of tiny blood fragments and tissue debris are helpful and should be sought out, as are any normal anatomic landmarks. Photographs, videotapes, and detailed drawings are helpful reminders in planning the strategy for cutting these adhesions.

Simultaneous laparoscopy is often prudent to prevent and immediately recognize perforation of the uterus. Flexible or semirigid scissors, the resectoscope, Versapoint, or the Nd:YAG laser are the operating instruments of choice, although some operators use the monopolar needle electrode at 40 to 50 W of cutting power, BLEND 1 or 2. The laser is initially set to deliver 30 to 50 W of power. The medium is instilled into the cavity by way of an operating sheath. Filmy and central adhesions should be cut first, always following the fluid flow. Marginal and dense adhesions should be tackled last, always cutting from below and moving upward. A second key to success is to maintain the hysteroscope in midchannel relative to the uterine walls. The cavity can usually be restored to reasonably normal architecture. Bleeding is not uncommon during this operation, particularly when cutting marginal adhesions, because the border between adhesion and myometrium is blurred.

The patient should be placed on conjugated estrogens during postoperative recovery. Placement of an IUD or uterine stent (Cook OB/GYN) (**Fig. 18.21**) within the cavity to keep the walls from adhering is a standard postoperative measure.

Cannulation of Fallopian Tube

Novy and associates described a technique for passing a special catheter into the tubal ostium and through the obstructed interstitial portion of the tube. The procedure was successful in 92% of the cases. Dumesic and Dhillon reported a tubal cannulation procedure in which they used a flexible guiding insert to facilitate passage of the cornual cannulation catheter. These techniques are useful for treating interstitial obstruction secondary to cellular debris and tubal spasm. The obvious advantage of this cannulation technique is its usefulness in treating cases that might otherwise require tubocornual anastomosis. Pregnancy rates range from 25% to 54% in 6 months.

Hysteroscopic Technique

A 5.5-F Teflon cannula with a metal obturator (Cook OB/GYN) is introduced through the operating channel of the hysteroscopic sheath. The obturator is removed. A 3-F catheter with a guide cannula wire is introduced into the

5.5-F cannula by

way of a Y-adapter on the end of the cannula, engaged into the tubal ostium, and gently advanced into the tube. When the cornual portion of the tube is negotiated or when resistance is encountered, the guide wire is withdrawn and indigo carmine dye injected through the 3-F catheter. Simultaneous laparoscopy allows one to see the dye exit the fimbriated end of the tube and confirm patency. Alternatively, one can place a radiologic plate beneath the patient and inject opaque dye (**Fig. 18.22**).

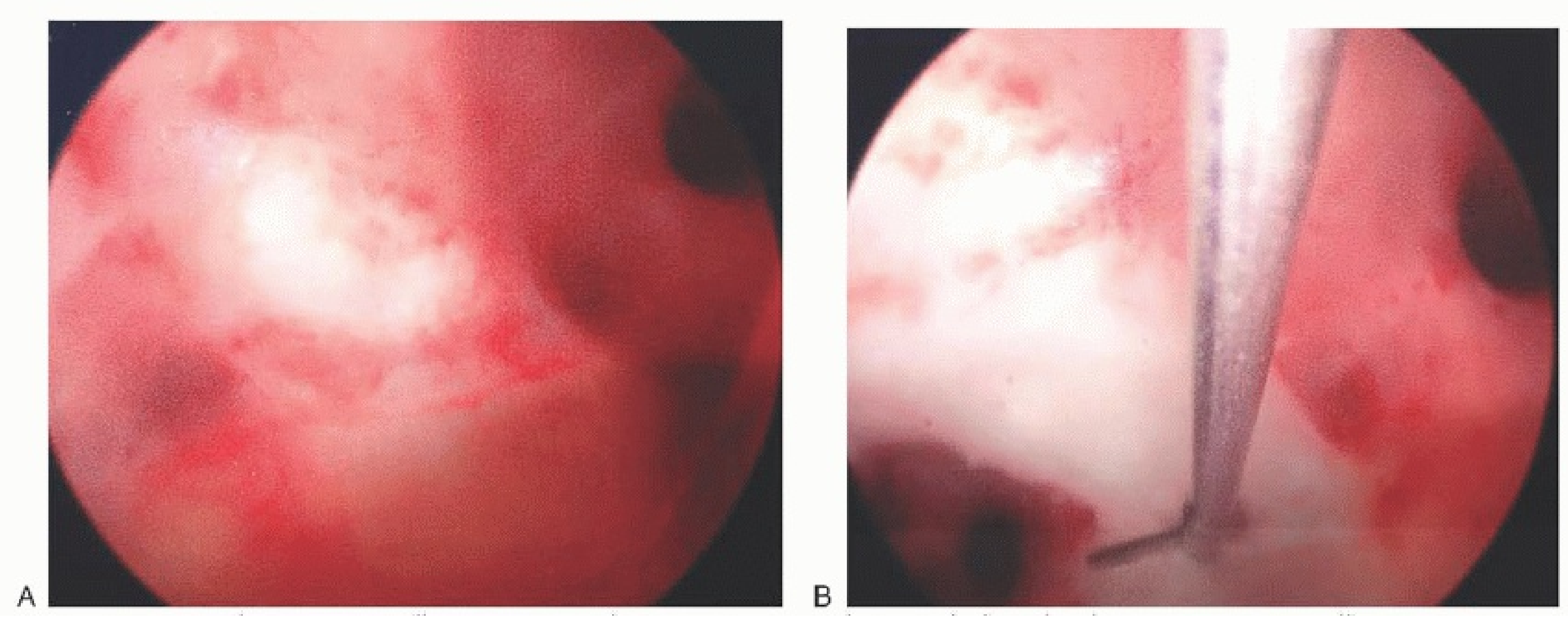

FIGURE 18.20 A: A thin transverse adhesion spanning the intrauterine cavity between the lateral and anterior-posterior walls. **B:** Hysteroscopic Mayo scissors used to incise the adhesion. Note: due to high risk for uterine perforation, no electrocautery is used.

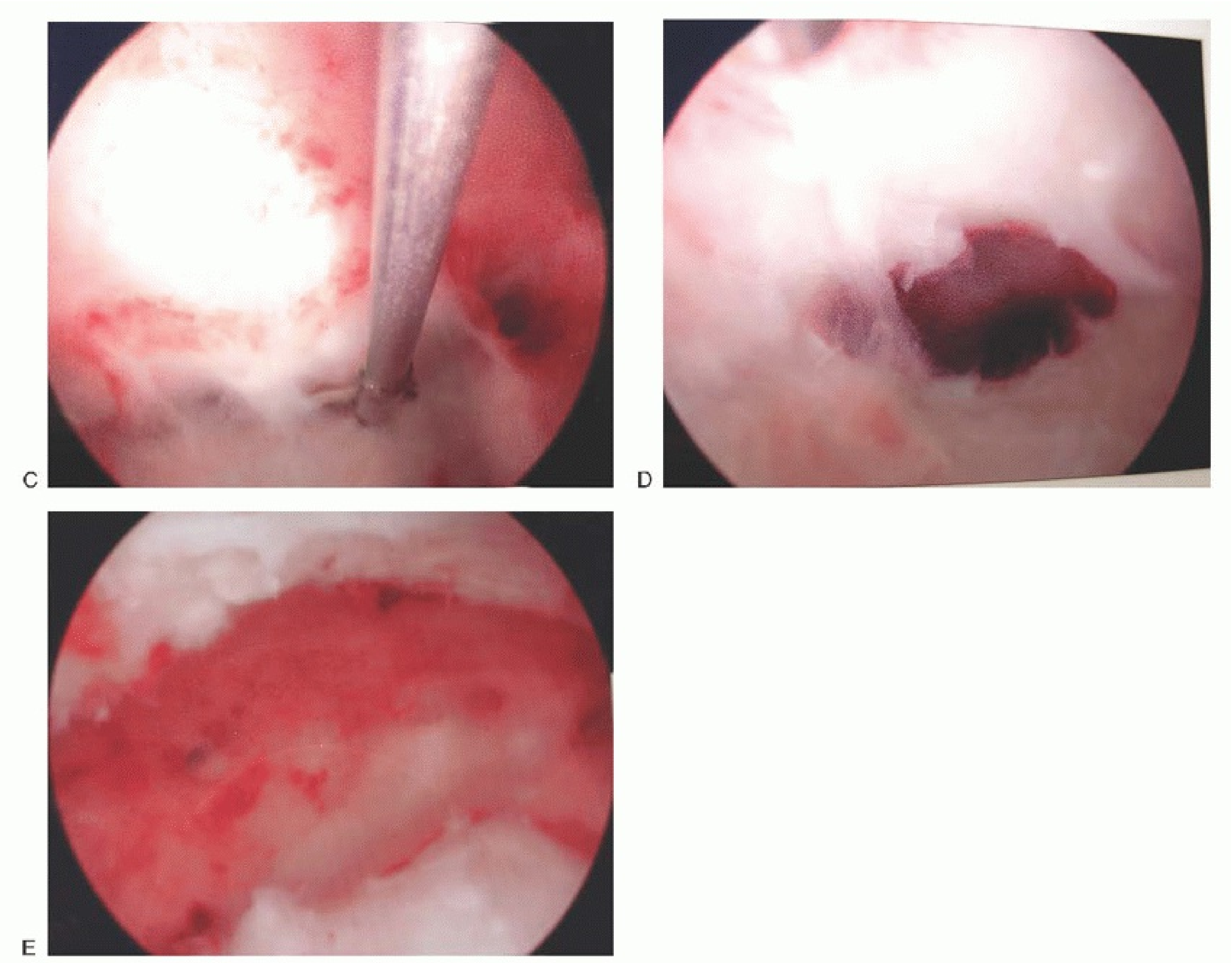

FIGURE 18.20 (*Continued*) **C:** Incision moving laterally. **D:** Opening into the upper/superior portion of the uterine cavity now visualized. **E:** Complete visualization of the newly opened intrauterine cavity.

FIGURE 18.21 This specially designed balloon may be placed within the uterine cavity. Uninflated, it can be used to prevent formation of adhesions following hysteroscopic lysis of adhesions. When inflated, it can be used to tamponade bleeding from the uterine wall. The intrauterine pressure will usually control bleeding. A 10-mL

Foley catheter (balloon inflated to 5 mL) may be used for this same purpose.

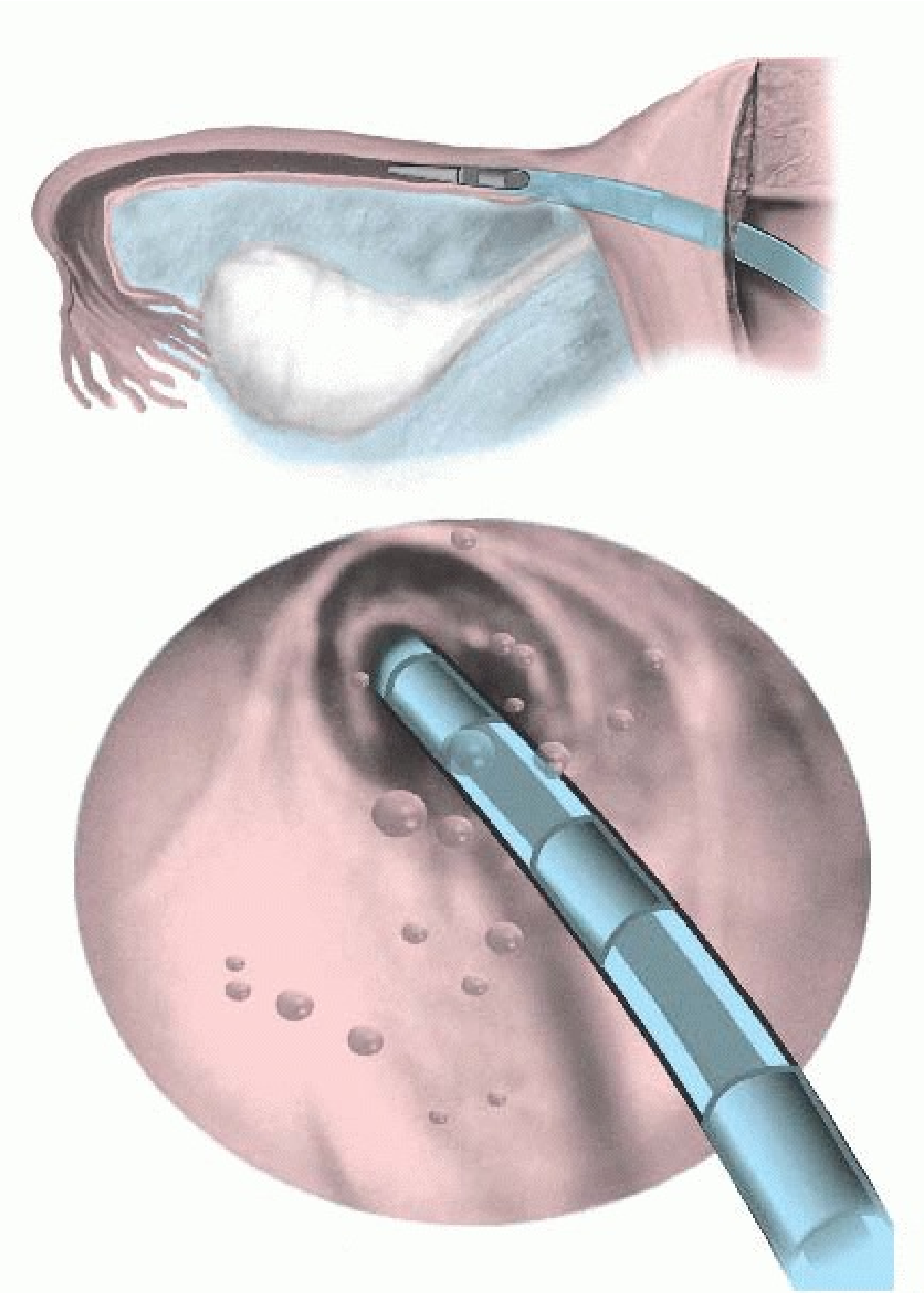

FIGURE 18.22 An inner guide wire is inserted via direct hysteroscopic view into the tubal ostium and advanced. An outer cannula is then advanced over the guide wire. Indigo carmine may be injected to demonstrate tube patency to an assistant viewing from above via laparoscopy. (Reprinted from Baggish MS, Valle RF, Guedj H. *Hysteroscopy: Visual perspectives of uterine anatomy, physiology and pathology,* 3rd ed. Philadelphia, PA: Lippincott Williams & Wilkins, 2007, with permission.) Copyright © 2007, Lippincott Williams & Wilkins.)

Uterine Polyps

Functional and nonfunctional polyps are a common cause of abnormal uterine bleeding. Functional polyps tend to be smaller than nonfunctional polyps. If a hysterogram is performed, a focal filling defect will be seen. Diagnosis is directly and readily made by hysteroscopy. Polyps protrude into the endometrial cavity. A functioning polyp has a lining identical to the surrounding endometrium. The nonfunctioning polyp presents as a white protuberance covered with branching surface vessels. Thick-walled vessels are usually seen within the depths of the polyps. Polyps are relatively easy to diagnose and treat. Gebauer and colleagues compared blind removal of uterine polyps (curettage and polyp forceps) with hysteroscopy. Polyps were diagnosed in 43% of cases by curettage. Out of 45 cases in which polyp forceps removed the polyp, remnants of or complete polyps remained in 31 cases. The authors concluded that hysteroscopically controlled polyp extraction was superior to blind techniques.

Endometrial polyps secondary to tamoxifen therapy in women undergoing treatment for breast cancer is a problem for which hysteroscopy may prove to be indispensable. Taponeco and colleagues reported on 414 breast cancer patients who underwent hysteroscopy (334 treated with tamoxifen and 80 controls). Significant differences were found in malignant (7.8%) and atypical (9%) hyperplastic polyps between the treated group versus controls (0 cases). The authors recommended that hysteroscopy and biopsy should be performed on any woman receiving tamoxifen who reports uterine bleeding. Garuti and colleagues compared the accuracy of blind sampling of the endometrium versus hysteroscopically directed biopsies in postmenopausal women receiving tamoxifen for breast cancer. The authors reported a sensitivity and negative predictive value of 100% with each technique. However, the specificity (80% versus 68%) and positive predictive value *(69%* versus 43%) were better for hysteroscopic versus blind sampling.

Hysteroscopic Technique

A multichannel operating hysteroscope is inserted into the uterine cavity, and a retractable electric snare loop is inserted through the 3-mm channel of the operating sheath. The polyp is encircled by the loop such that the loop encompasses the polyp base as it is tightened. The polyp is cut off at the base with 30 to 40 W of power for cutting current. The snare is then removed, and an alligator jaw forceps is inserted. The polyp is grabbed by the forceps. The hysteroscope is withdrawn, removing with it the freed polyp, which is sent to the pathology laboratory for histologic evaluation. The site of removal is inspected again and the procedure terminated. If any bleeding is observed, a 3-mm ball electrode is applied to the site for coagulation (40 to 50 W). Alternatively, a polyp may be cut at its base with a needle electrode or laser fiber. The polyp may also be shaved by means of the resectoscope (**Fig. 18.23**).

Myoma Uteri

Submucous myomas characteristically appear as white spherical masses covered with a network of fragile thin-walled vessels when viewed by hysteroscopy. Myomas typically are sessile or pedunculated. A hysterogram shows a filling defect that is not dissimilar to that produced by a polyp. Unfortunately, blind dilation and curettage is a grossly inaccurate method of diagnosing this disorder. Although subserous and intramural myomas rarely produce alarming symptoms, even when they attain relatively large size, smaller lesions in the submucous location invariably cause considerable bleeding.

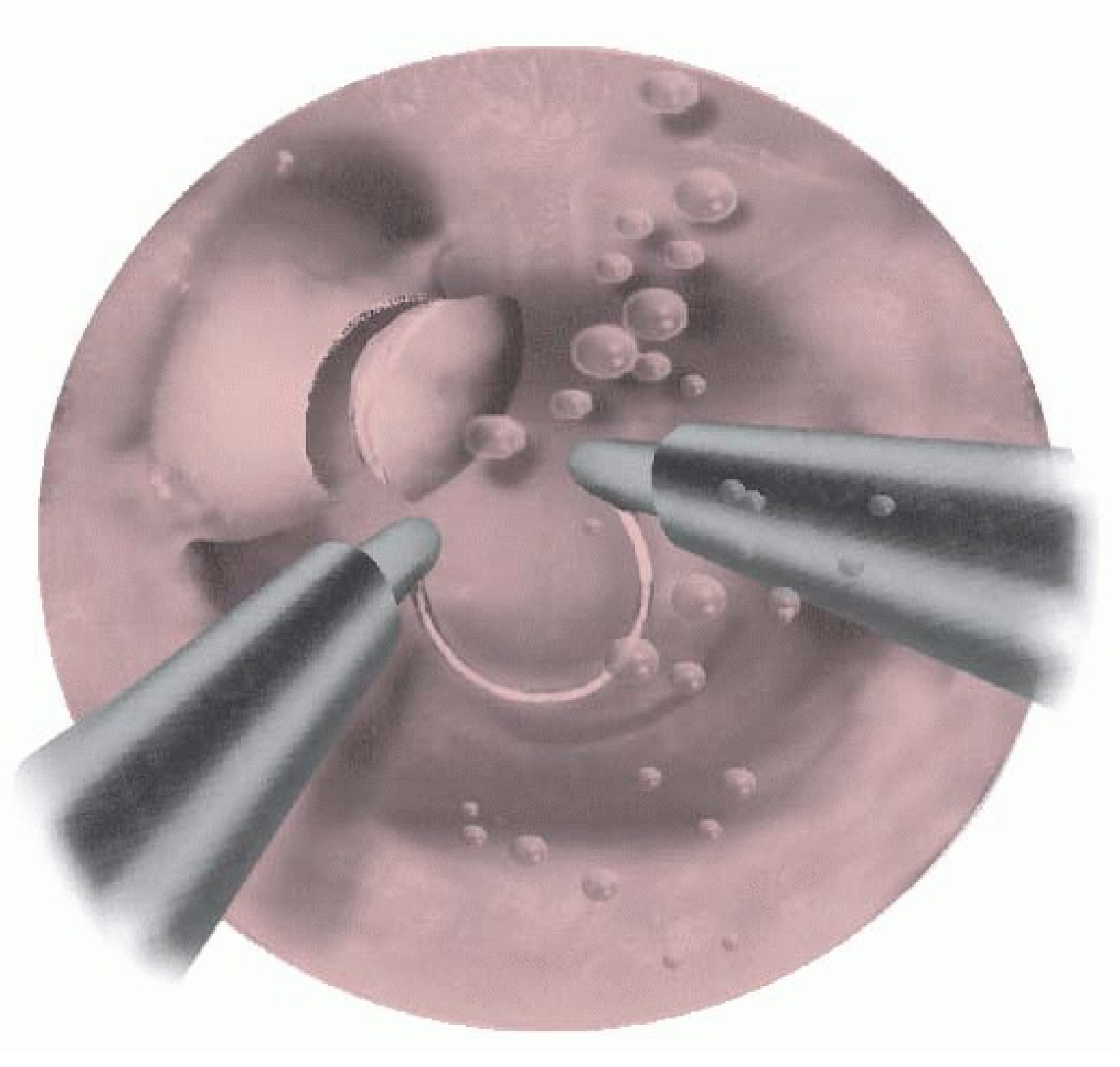

FIGURE 18.23 A functioning polyp on the right corpal wall of the uterus is resected by means of a resectoscopic

loop electrode. Note that the technique is the same as the one employed for shaving a submucous myoma. (Reprinted with permission from Baggish MS, Valle RF, Guedj H. *Hysteroscopy: visual perspectives of uterine anatomy, physiology and pathology,* 3rd ed. Philadelphia, PA: Lippincott Williams & Wilkins, 2007, with permission.)

In the past, a diagnosis of submucous myoma was usually followed by a recommendation for hysterectomy. Today, hysteroscopic surgery offers a therapeutic alternative to that radical approach. Gonadotropin-releasing hormone (GnRH) analogues such as leuprolide acetate (Lupron) or goserelin acetate (Zoladex) have been recommended as supplementary preoperative medical therapy. The general plan is to treat symptomatic patients for 2 to 3 months preoperatively to reduce the size and vascularity of the lesion during surgery. All patients should be given detailed information concerning the need for typing and holding of blood and the possibility of hysterectomy if intractable bleeding occurs.

Valle in 1990 reported data on 59 cases of abnormal bleeding, dysmenorrhea, and infertility that were diagnosed as submucous myomas. Hysteroscopy eliminated or markedly decreased bleeding in 52 of these cases. In 1989, Baggish and Sze treated 71 patients with symptomatic myomas and four patients with incidental submucous myomas. The treatment methods used with the multichannel hysteroscope were Nd:YAG laser (n = 41), monopolar loop (n = 6), monopolar needle (n = 6), bipolar needles (n = 10), and electrosurgery or scissors and laser (n = 12). As with Valle's series, results were excellent; 65 of 75 (87%) returned to normal menses postoperatively.

Emanuel and colleagues reported 285 women who underwent hysteroscopic resection of submucous myomas. The median follow-up was approximately 4 years (1 to 104 months), and 85.5% of the operated patients required no further surgery. Clark and associates treated 37 women using the bipolar Versapoint electrode via ablation or excision. Improvement of bleeding symptoms was reported in 78% of the patients, and 92% were satisfied with the treatment. No significant complications were reported.

Hysteroscopic Technique

Several variations of hysteroscopic procedures are now available to manage submucous myomas. Resectoscopic instrumentation has vastly improved in recent years compared with earlier instruments. Self-flushing sheaths, straight and offset cutting loops, and diminished-diameter, low-profile scopes are among these recent improvements. In addition, electrosurgical generators have been modernized and are safer devices than instruments from the 1970s and 1980s. Under video control, the resectoscopic technique consists of progressive shaving of the myoma and harvesting pieces of tissue for subsequent histologic evaluation. For fundal myomas, the straight electrode is the most effective device, whereas the angulated electrode is preferred for lesions located on the anterior or posterior walls (**Fig. 18.24A**). The electrode should be activated only while returning toward the hysteroscope, never while advancing outward away from the lens. The greatest disadvantage to this technique centers on the need to repeatedly remove the shaved nuggets of tissue (**Fig. 18.24**).

Other electrosurgical techniques may be employed in conjunction with the large isolated-channel, flushing hysteroscope. Three-mm needles, shaving loops, and bipolar electrodes may be used to perform all of the optional operations described above for the resectoscope (**Fig. 18.25**). The fine-needle electrode can be substituted for laser fiber to excise pedunculated or section sessile myomas. The 3-mm retractable cutting loop can perform shaving procedures in a fashion similar to that of the resectoscope loop. The bipolar needles can be plunged many times into the substance of the submucous myoma of any size to coagulate the interior of the myoma (myolysis).

If postoperative bleeding occurs, a 10-mL Foley balloon is placed in the cavity and blown up to 5 mL for 6 to 12 hours. If the cavity is large, a 30-mL balloon inflated with 10 to 15 mL of water can be used. Some gynecologic surgeons prefer to do a simultaneous laparoscopy when large myomas (3 to 5 cm) are resected and extracted. Regardless of myoma size, a simultaneous laparoscopy should be performed whenever concern for perforation exists. The central fundal myoma is associated with the greatest risk of uterine perforation.

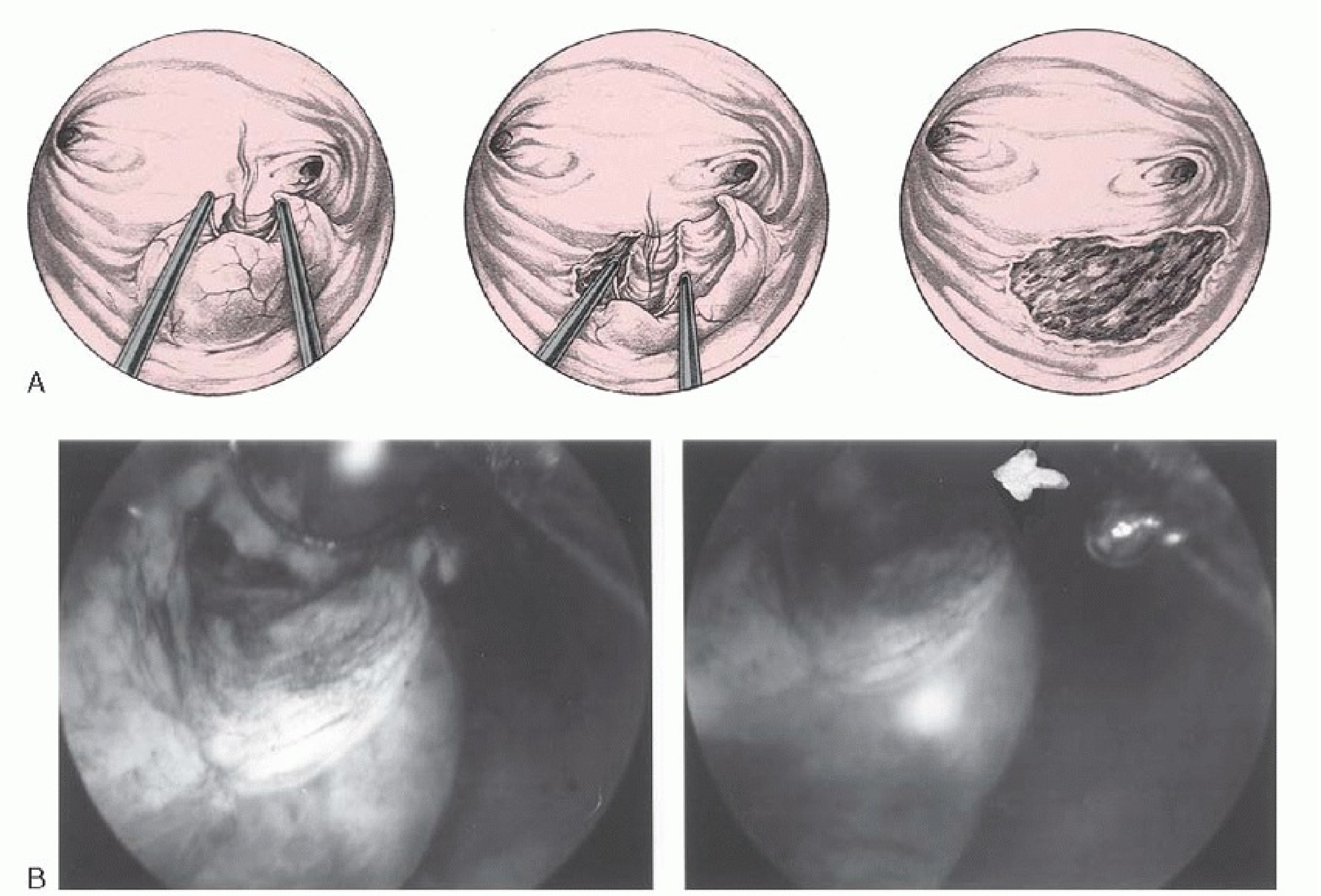

FIGURE 18.24 A: The shaving technique for the elimination of a submucous myoma is shown using an angulated loop electrode via the resectoscope. (Reprinted from Baggish MS, Barbot J, Valle RF. *Diagnostic and operative hysteroscopy,* 2nd ed. St. Louis, MO: Mosby-Year Book, 1999, with permission. Lippincott Williams & Wilkins, 2007.) **B:** A chunk of tissue has been cut out of this myoma. The resectoscopic loop is seen above **(left)**. The picture to the right shows the loop extended farther into the cavity (*arrow*).

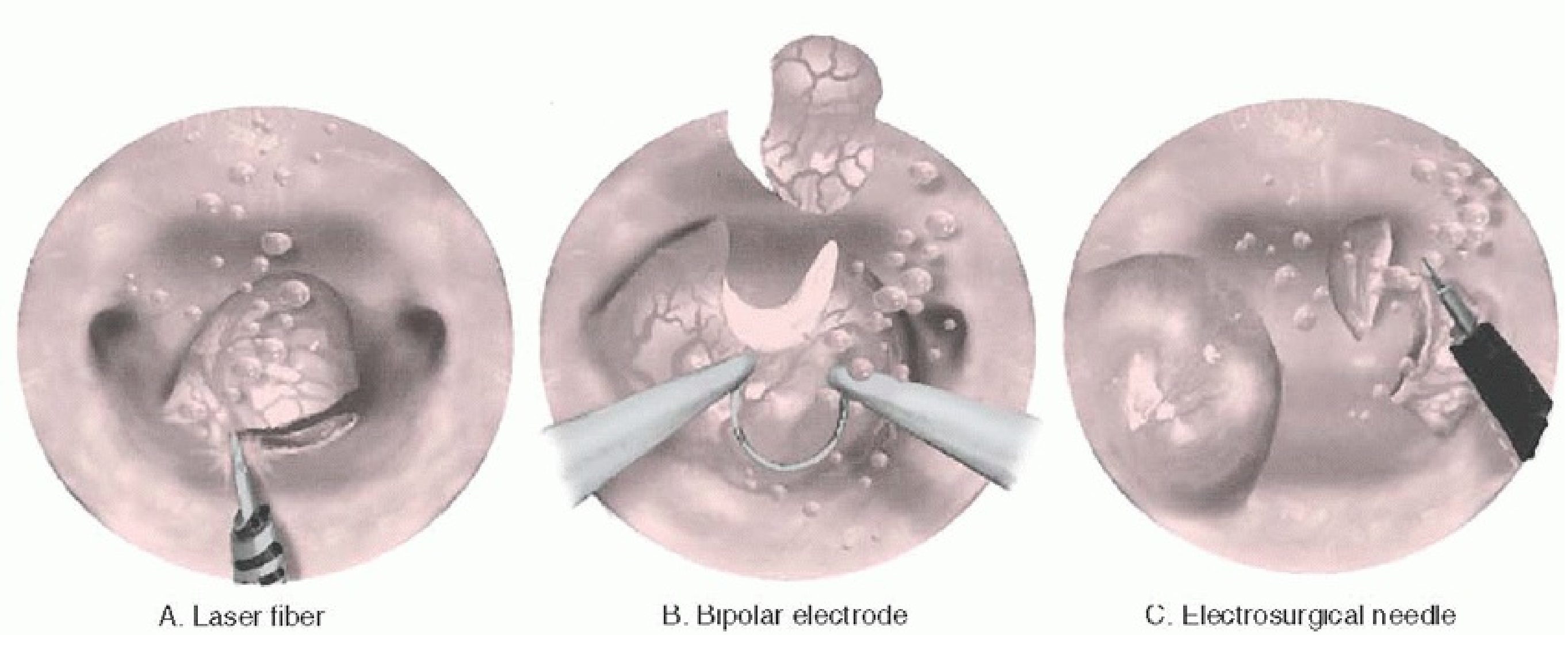

A. Laser fiber B. Bipolar electrode C. Electrosurgical needle

FIGURE 18.25 A-C: Several techniques and instruments may be used to deal with submucous myomas. **A:** shows a laser fiber within an irrigation cannula cutting a myoma at its base. **B:** shows an electrode shaving a myoma. **C:** shows an electrosurgical needle cleaving a piece of a submucous myoma. (Reprinted from Baggish MS, Valle RF, Guedj H. *Hysteroscopy: visual perspectives of uterine anatomy, physiology and pathology,* 3rd ed. Philadelphia, PA: Lippincott Williams & Wilkins, 2007, with permission.)

Reports caution that uterine rupture can occur during pregnancy after hysteroscopic myomectomy. This is particularly the case when the operator attempts to resect the intramural portion of the submucous myoma. As such, patients should inform their obstetricians of a history of a hysteroscopic myomectomy in the event they become pregnant. Regarding risk of malignancy from submucosal fibroids, the risk of leiomyosarcoma is less than 1%. Nevertheless, any myoma or part of a myoma that is excised should be sent to the pathology laboratory for evaluation. This, of course, includes resectoscopic fragments.

Sterilization

Surgical methods of performing female sterilization from tubal ligation to total salpingectomy are discussed in other chapters of this book. These methods are well established and in widespread use with low failure rates. Attempts to perform female sterilization hysteroscopically using plugs or causing proximal obstruction by electrical or chemical means have been attempted in the past. High complication and failure rates resulted in cessation of their use. In November 2002, the Food and Drug administration (FDA) approved the use of the Essure microinsert, which is inserted hysteroscopically. Essure is widely used today. A detailed description of the Essure microinserts and the technique for placing them via hysteroscopy can be found in Chapter 27 of this text.

Endometrial Ablation

Since the first practical method of hysteroscopic ablation was described in 1981, several thousand cases have been performed by a variety of techniques, including the Nd:YAG laser, the resectoscopic roller ball or loop, and, most recently, the long hysteroscopic ball electrodes. Garry and associates in 1995 reported 600 endometrial laser ablations performed on 524 women. No major operative morbidity was reported. The success rate (mean age, 43 years) was 83.4%. Baggish and Sze have performed 568 ablations; 401 of these were performed with the Nd:YAG laser and 167 by electrosurgery. Excellent results were obtained in 89% of the women treated, and amenorrhea was achieved in 58%. Again, no major operative complications were observed. Magos and coworkers reported 250 cases of endometrial resection with a 92% improvement in abnormal bleeding. However, data obtained from the Royal College of Obstetricians and Gynaecologists' MISTLETOE (Minimally Invasive Surgical Technique—Laser, Endothermal, or Endoresection) Study in 1997 revealed a 6.4% rate of significant complications associated with endometrial resection alone and a rate of 11.4/1,000 with emergency hysterectomy. This compares with complication rates of 2.7% and 2.1% for laser and rollerball, respectively. The latter two techniques had emergency hysterectomy rates of 1.3/1,000 (i.e., 11 times less than endometrial resection). Nonhysteroscopic minimally invasive techniques for endometrial ablation have emerged in recent years and replaced hysteroscopic endometrial ablation in most settings. These techniques, which include thermal balloon ablation, microwave endometrial ablation, and radiofrequency electromagnetic energy, are reviewed in detail in Chapter 26.

Hysteroscopic Technique

STEPS IN THE PROCEDURE

Operative Hysteroscopy

- Patient in lithotomy position.
- Bimanual examination: uterus anteverted or retroverted.
- Position fluid collection bag under the buttocks.
- Prior to starting, verify the following: hysteroscope assembly and outflow inflow tubes correctly connected, light cord and camera attached to telescope, and white balance.
- Verify correct distention media.
- Verify pressure, flow, and fluid deficit alarm settings on automated pump delivery system.
- Cervix visualized with bivalve speculum or Sims retractor.
- Tenaculum applied to the anterior lip of the cervix.
- Dilation of cervix, if required (dilation not required for diagnostic scope); do not overdilate.
- Place hysteroscope in external os, with distention media flowing; insert under direct visualization; countertraction applied using tenaculum (verify that inflow valve is open and outflow valve is closed).
- Once inside uterine cavity, remove speculum or Sims retractor with the hysteroscope in place; verify/orient position by identifying the tubal ostia.
- Insert operative instruments (must have rubber stopper over port prior to opening instrument port valve); maintain the distal end of the hysteroscope in constant visualization while inserting the instrument.
- Operative portion: If visualization is cloudy, open outflow valve to clear, then reclose; may leave slightly open for fluid circulation if necessary.
- Attempt to only touch intrauterine walls when necessary to avoid bleeding, which will cloud the field.
- Check fluid deficit: Approximately every 5 minutes, halt procedure at a deficit of 1000-1500 mL (hypoosmolar) or 2,500 mL (isoosmolar) depending on distention media used.
- Termination of procedure: fluid deficit calculated and recorded in operative notes/dictation.

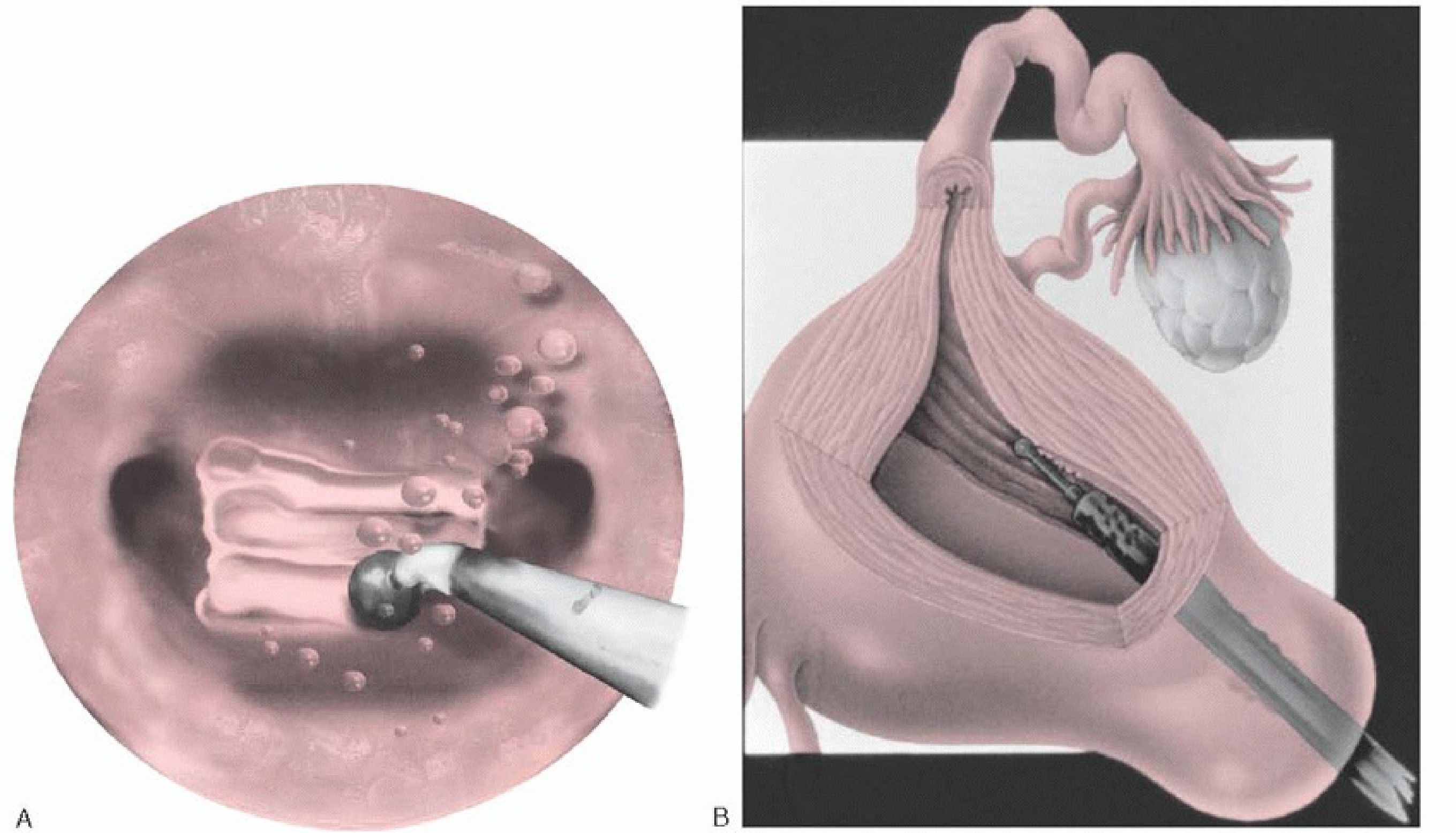

FIGURE 18.26 A: The ball electrode is dragged from side to side via moving the entire hysteroscope, thereby ablating the uterine fundus. **B:** The anterior and posterior walls are ablated by dragging the energized ball electrode from above downward. This creates 2- to 3-mm furrows in the endometrium. Conduction heat damage

can extend another 1 to 2 mm. (Reprinted from Baggish MS, Valle RF, Guedj H. *Hysteroscopy: visual perspectives of uterine anatomy, physiology and pathology,* 3rd ed. Philadelphia, PA: Lippincott Williams & Wilkins, 2007, with permission.)

All patients who might be candidates for endometrial ablation should have been managed first by hormonal treatment in an attempt to control the abnormal uterine bleeding. If this strategy fails, and if the woman does not desire to bear children, then she is a candidate for endometrial ablation. A preoperative diagnostic hysteroscopy, endometrial sampling, or both should be performed to exclude endometrial carcinoma or atypical hyperplasia, and all pertinent hematologic studies and consultations should be performed. All patients are pretreated to atrophy the endometrium with medication such as a GnRH agonist.

A simultaneous laparoscopy is not performed during endometrial ablation unless a perforation or other transmural injury is suspected. Depending on the technique selected, either 5% mannitol or 0.9% saline is used as the distending medium. The operating hysteroscope or resectoscope is inserted into the uterine cavity. One method to treat the fundus is by dragging the laser fiber or the ball electrode from side to side (cornu to cornu) (**Fig. 18.26A**). The anterior and lateral walls are ablated next, before the posterior wall. Ablation should not be extended below the internal os into the cervix (**Fig. 18.26B**). Power settings for the electrosurgical generator range from 50 to 150 W, depending on the size of the ball, barrel, or loop electrode (**Figs. 18.27** and **18.28**). Laser power is set at 40 to 60 W. The goal of the ablation operation is to destroy the visible endometrium, including the cornual endometrium, to a depth of 1 to 2 mm. The conduction heat will actually spread deeper, usually to 3 to 5 mm, depending on how long the device remains on the tissue. This penetration translates into extensive superficial myometrial destruction and coagulation of the radial branches of the uterine cavity (**Fig. 18.29**). When the endometrium sloughs, regeneration is prevented because basal and spiral arterioles do not survive the 100°C heat exposure. Over a period of 6 to 8 weeks, the uterine walls scar and shrink. Subsequent sampling or hysteroscopy is possible after endometrial ablation (**Fig. 18.30**). The mean duration of the operation is about 30 minutes. Patients usually are sent home on the day of surgery. The operation is usually completed with little or no blood loss.

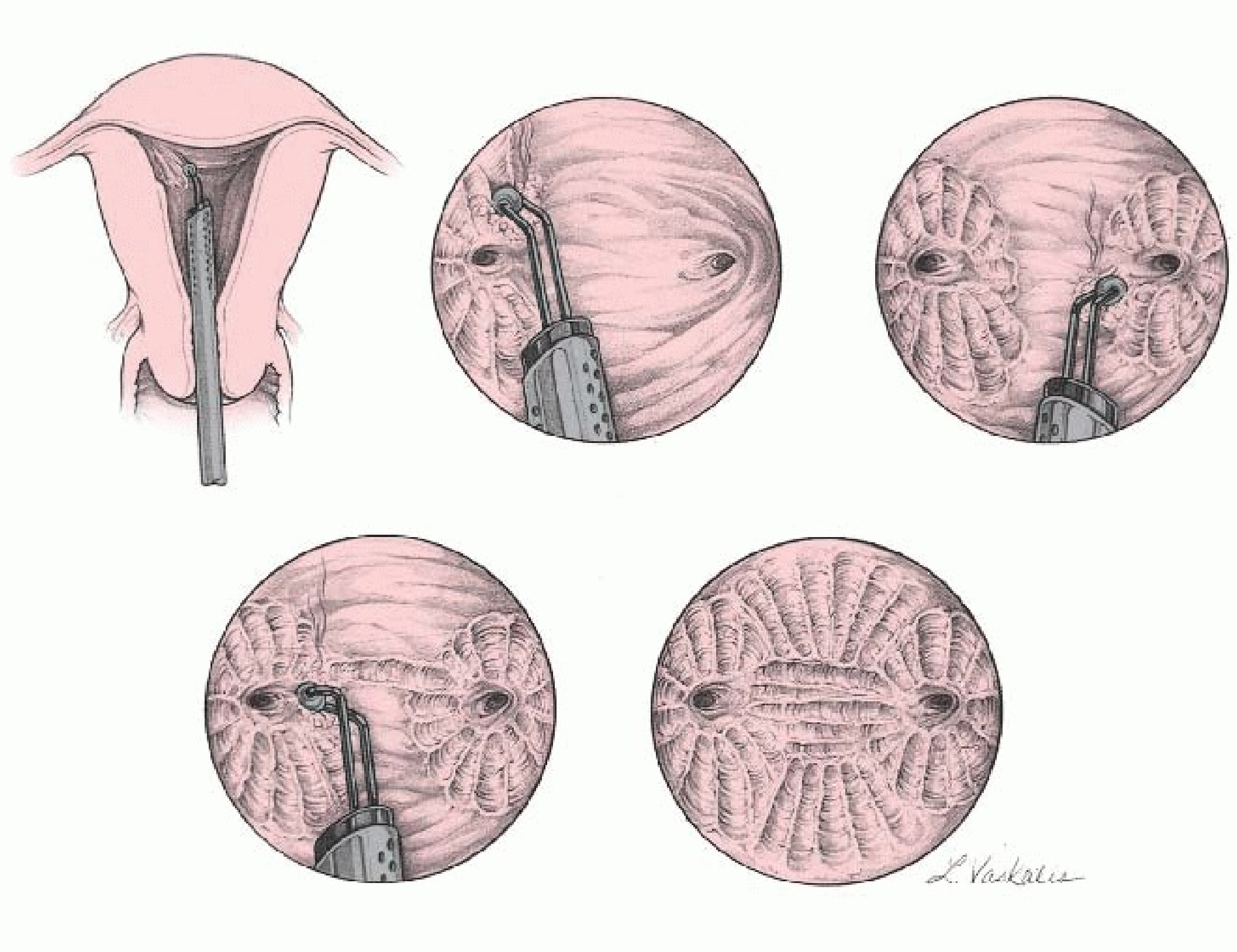

FIGURE 18.27 The resectoscope with ball electrode attached is inserted into the uterine cavity. Initially, the cornu and fundus are carefully ablated, taking care to keep dwell time low to reduce the risk of deep heat conduction injury. Next, the anterior wall is ablated, followed by the posterior wall. (Reprinted from Baggish MS, Valle RF, Guedj H. *Hysteroscopy: Visual perspectives of uterine anatomy, physiology and pathology,* 3rd ed. Philadelphia, PA: Lippincott Williams & Wilkins, 2007, with permission.)

Miscellaneous Procedures

Intrauterine Device Removal

The gynecologist is occasionally called to search for and remove an IUD with an indicator string that is not seen in the cervix. In such circumstances, the operating hysteroscope is a vital tool with which to locate the device and remove it under direct visualization. The hysteroscope is inserted, and the device is viewed. If a string is seen, an alligator jaw forceps is inserted, and the string is grasped. The hysteroscope is withdrawn, pulling the device through the uterine cavity and the cervix to the exterior. If the IUD is embedded, then a rigid grasping forceps is required. The IUD is located, and the large jaws of the rigid instrument grab the extruded portion of the IUD itself. Strong pressure is exerted on the jaws as the sheath of the hysteroscope is slowly withdrawn from the uterus, into the cervix, and out of the vagina.

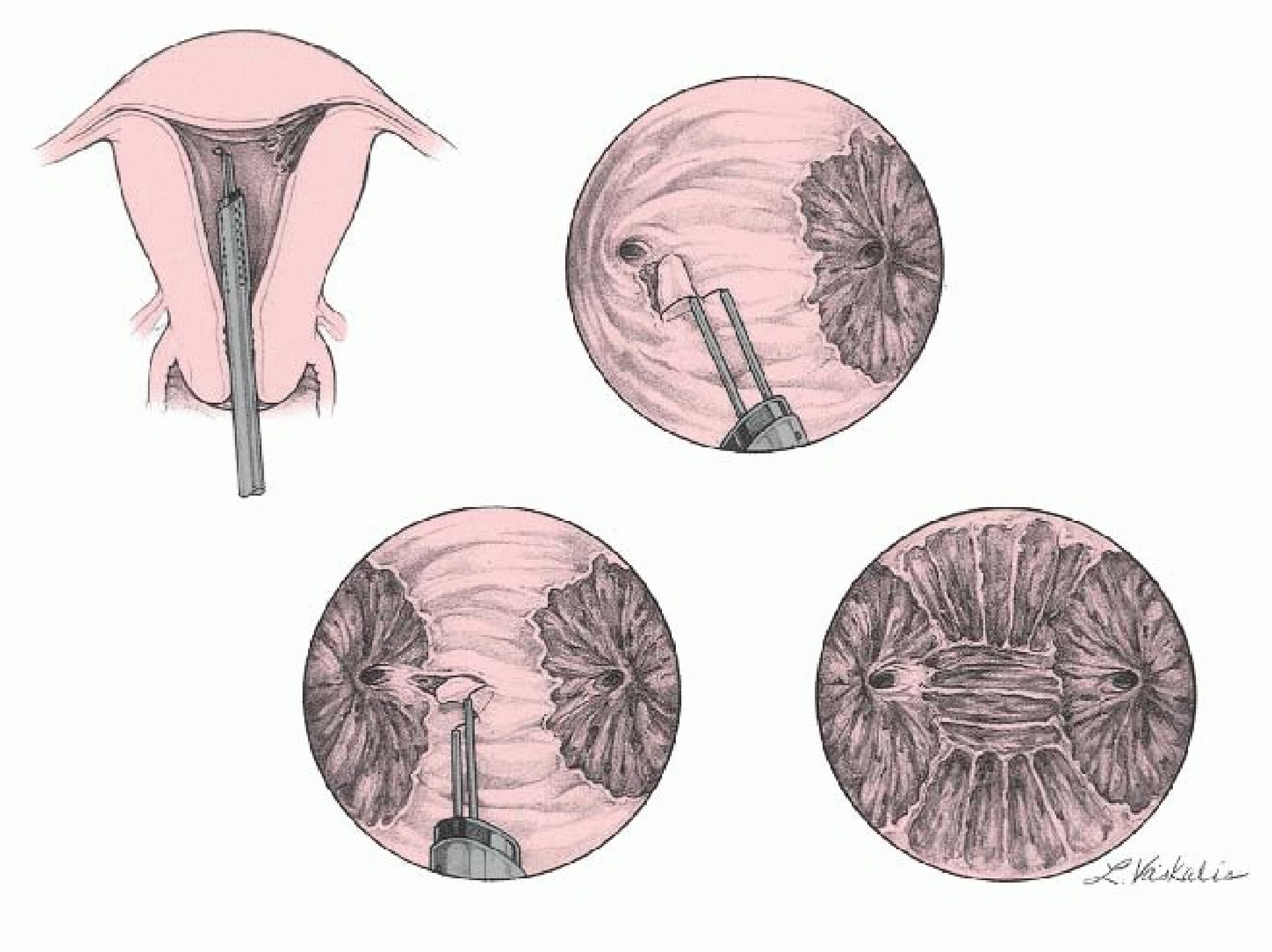

FIGURE 18.28 Endometrial resection is performed in a manner similar to ablation; however, instead of a ball electrode, a cutting loop is substituted. This is clearly a riskier procedure compared with ablation by either laser or ball electrode, particularly relative to deep myometrial resection with the accompanying risks of hemorrhage and/or perforation. (Reprinted from Baggish MS, Valle RF, Guedj H. *Hysteroscopy: visual perspectives of uterine anatomy, physiology and pathology,* 3rd ed. Philadelphia, PA: Lippincott Williams & Wilkins, 2007, with permission.)

Biopsy of Intrauterine Lesions

When a tumor is suspected, the operative hysteroscope is inserted into the cavity, a 9-F biopsy forceps is directed to the tumor site, and multiple biopsy specimens are obtained in a fashion analogous to that used with colposcopic biopsies. A 9-F plastic cannula is inserted by way of the operating channel, and strong suction is applied to the mouth of the cannula

by means of a 30-mL syringe. The cannula is removed, and the contents are flushed out with saline into a bottle of fixative. Similarly, a 9-F curette can be inserted under direct vision. Alternatively, a diagnostic hysteroscope can be inserted into the uterus. The site of pathology is noted. The endoscope is withdrawn, a Novak curette is inserted into the cavity, and biopsy specimens are taken at the previously located site. Finally, the hysteroscope is pulled back to the level of the internal cervical os, a small Novak curette is inserted alongside the hysteroscope, and a directed biopsy specimen is obtained.

FIGURE 18.29 The uterus was removed 5 days after an Nd:YAG laser ablation. Note the extensive laser injury involving about half the thickness of the myometrium. Laser penetration depends not only on power but also on the length of time the laser beam remains in contact with the tissue.

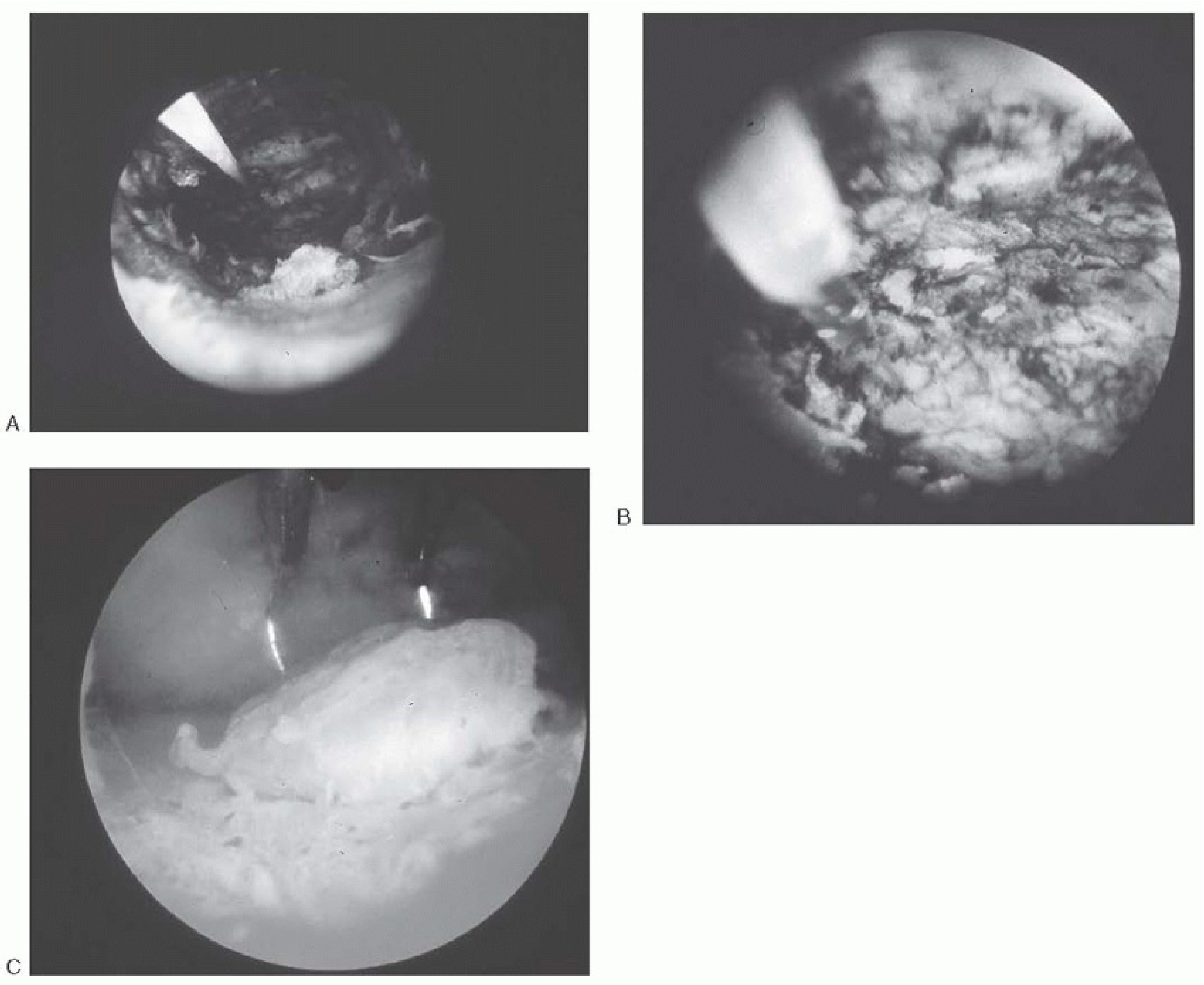

FIGURE 18.30 A: Complete destruction of the endometrium has been afflicted by means of Nd:YAG laser ablation. The fiber is seen at the 11 o'clock position. **B:** Close-up view of ablated endometrium shown in part A. Note the laser fiber to the left. **C:** Endometrial resection is performed via a shaving technique utilizing the resectoscope.

COMPLICATIONS

Unfortunately, accurate data concerning complications are hard to obtain. As greater numbers of gynecologists have begun to perform operative hysteroscopy, the rate of complications has increased. Complications include bleeding, uterine perforation, creation of false passages, and excess fluid absorption and subsequent pathologic responses. Propst and colleagues reviewed data on 925 women who had hysteroscopies. Operative complications occurred in 2.7% of patients.

Excessive fluid absorption was the most common complication. Myomectomy and resection of uterine septum had greatest odds for complication (odds ratio [OR] 7.4).

Intraoperative and Postoperative Bleeding

The most common complications inherent to hysteroscopic surgical procedures are intraoperative and postoperative bleeding. Intraoperative bleeding can be managed by aspirating the blood and by increasing the pressure of the distending medium so that it exceeds arterial pressure and compresses the walls of the uterus sufficiently to stop bleeding. The bleeding vessel may then be coagulated with a 3-mm ball electrode and the use of forced coagulation at 30 to 40 W of power or by multiple jabs with bipolar needles at 20 to 30 W of power with the generator set for automatic bipolar. If the counterpressure of the medium is relaxed (at the termination of the procedure) and bleeding continues, then control is best obtained by inserting an intrauterine balloon initially inflated to 2 to 5 mL. If this pressure does not promptly stop the bleeding, then a larger balloon can be distended to 10 mL until the bleeding has stopped (**Fig. 18.21**). More distension may be required for larger uteri. Care must be taken because overinflation of an intrauterine balloon can itself rupture the uterus. The balloon remains in place for 6 to 8 hours, is partially deflated for 6 hours, and, finally, is totally deflated before removal. When the bleeding is pulsatile, the source is arterial rather than venous. If this type of bleeding is not immediately controlled by balloon compression, then emergent hysterectomy or uterine artery embolization will usually be required. Delayed postoperative bleeding is most commonly associated with endometrial slough (after ablation), chronic endometritis, or spontaneous extrusion and expulsion of the intramyometrial portion of a previously resected submucous myoma. Bleeding-clotting studies should be obtained in cases of late postoperative bleeding, particularly if these studies were not performed preoperatively in women with a diagnosis of abnormal uterine bleeding (preoperative endometrial ablation or myomectomy).

A French group in 2003 prospectively studied a decade of operative hysteroscopies (2,116 cases). Thirteen cases of major bleeding were reported, with six requiring intrauterine catheter placements. The highest-risk procedure for associated hemorrhage was hysteroscopic adhesiolysis.

Uterine Perforation

Uterine perforation can occur during any operative hysteroscopy procedure but is most common during septum resection, myomectomy, and lysis of adhesions. The best insurance against this complication is simultaneous laparoscopy. Among novice operators, perforation can occur even during insertion of the hysteroscope. With appropriate care, this sort of perforation should not happen, because the cervix and internal os should be negotiated under direct visualization, and the cavity should likewise be entered under direct visualization. Examination under anesthesia is also simple and lets the operator know the direction of the uterine axis.

As we noted above, the most dangerous perforations are those associated with lasers and electrosurgical devices. The risk of this type of injury can be reduced by not activating the energy device during a thrusting or forward movement. The foot pedal is activated only during the return phase of the laser fiber or electrosurgical electrode. If a perforation does happen with an energy device, then laparotomy or laparoscopy is required to ensure that no injury has been inflicted on the intestine, bladder, or ureter (**Fig. 18.31**).

A risk of perforation is associated with the septum transection in its final phase at the level of the uterine fundus because the operator may have some difficulty determining where the septum ends and the myometrium begins. This risk is constant regardless of the cutting instrument used. The operator rapidly becomes aware that uterine perforation has occurred because distention becomes difficult to maintain and the flow of the distending medium exits at the perforation site (**Fig. 18.32**). An alert assistant viewing by laparoscope should warn the hysteroscopist of impending perforation the moment an increasing intensity of light transmission through the thinning uterine wall is observed. If perforation is unnoticed and if simultaneous laparoscopy is not performed, a serious complication is even possible with a nonenergy instrument, but this is far less common than those occurring with lasers or electrodes. Nevertheless, if a perforation is suspected, that patient should be carefully observed in the hospital. Injuries to the iliac vessels can occur as the result of uterine perforation. An unexplained falling blood pressure, together with medium leakage, should alert the surgeon to this possibility. Perforation of the uterus during hysteroscopy can place a woman at an increased risk for uterine rupture during a future pregnancy.

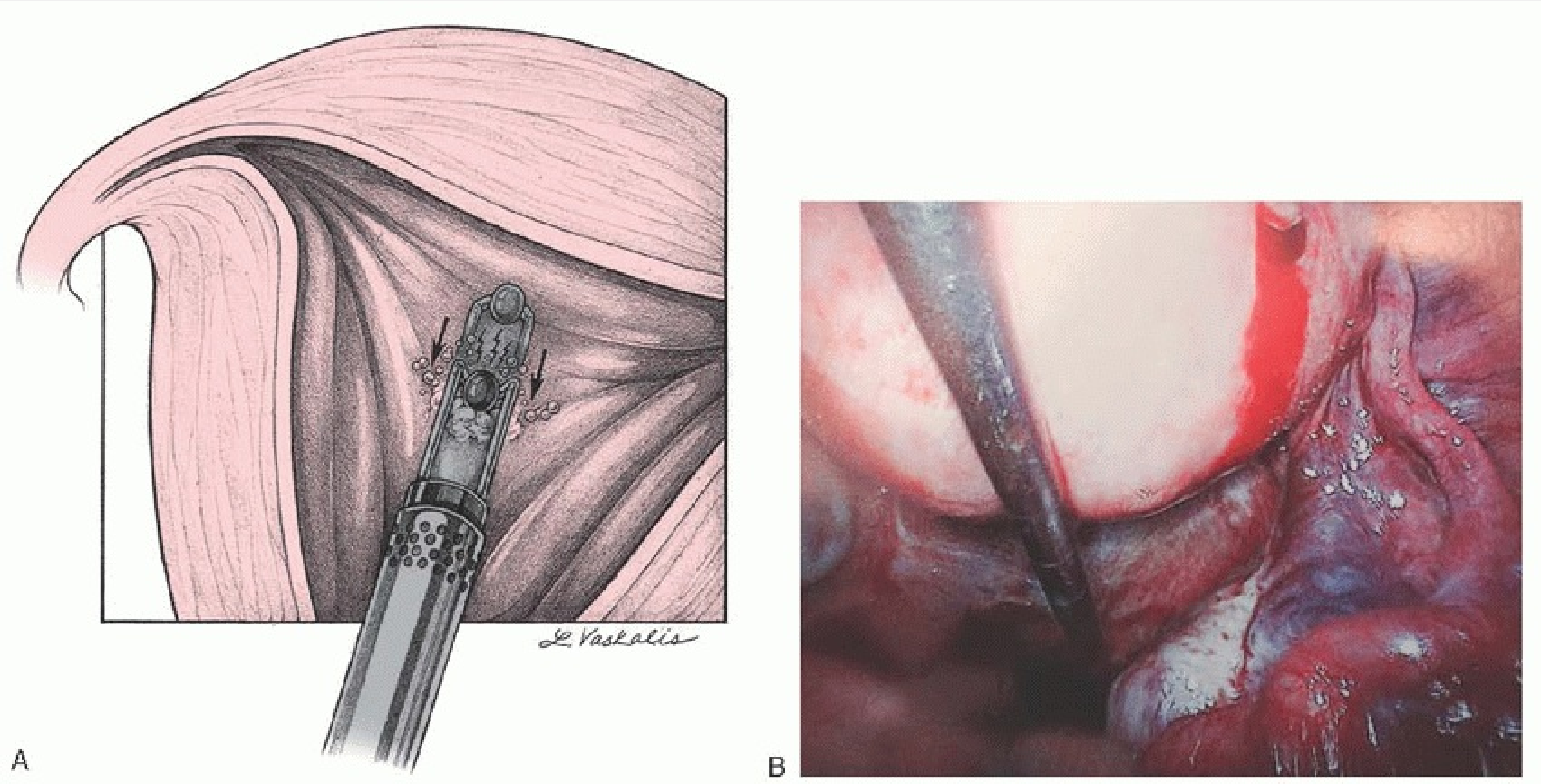

FIGURE 18.31 A: The operator should never apply power to an energy device while advancing the electrode. The power can safely be applied as the electrode returns toward the sheath. (Reprinted from Baggish MS, Valle RF, Guedj H. *Hysteroscopy: Visual perspectives of uterine anatomy, physiology and pathology,* 3rd ed. Philadelphia, PA: Lippincott Williams & Wilkins, 2007, with permission.) **B:** Laparoscopic image of a uterine perforation that occurred while using the hysteroscopic resection loop.

As uterine perforation often occurs during the dilation prior to actually placing the hysteroscope, there has been much interest in optimizing the dilatation process to avoid perforation and other complications such as creating a false passage and cervical laceration. Use of misoprostol, a synthetic prostaglandin E_1, has been studied extensively as a cervical dilator prior to hysteroscopy to prevent complications associated with dilatation. A 2011 systemic review by Selk and Kroft did not rule out a beneficial effect of misoprostol on cervical dilation or surgical complications in operative hysteroscopy, but the authors were unable to conclude that evidence currently supports the routine use of misoprostol prior to hysteroscopy.

Management of Fluid Overload

Fluid overload associated with hysteroscopy is rare, with 1 study of 21,676 patients reporting the complication in 0.02% of cases. However, the pathophysiologic ramifications for the patient can be severe and life-threatening. Therefore, the gynecologic surgeon must be vigilant in preventing this important complication. The risk of complications varies with the distention medium.

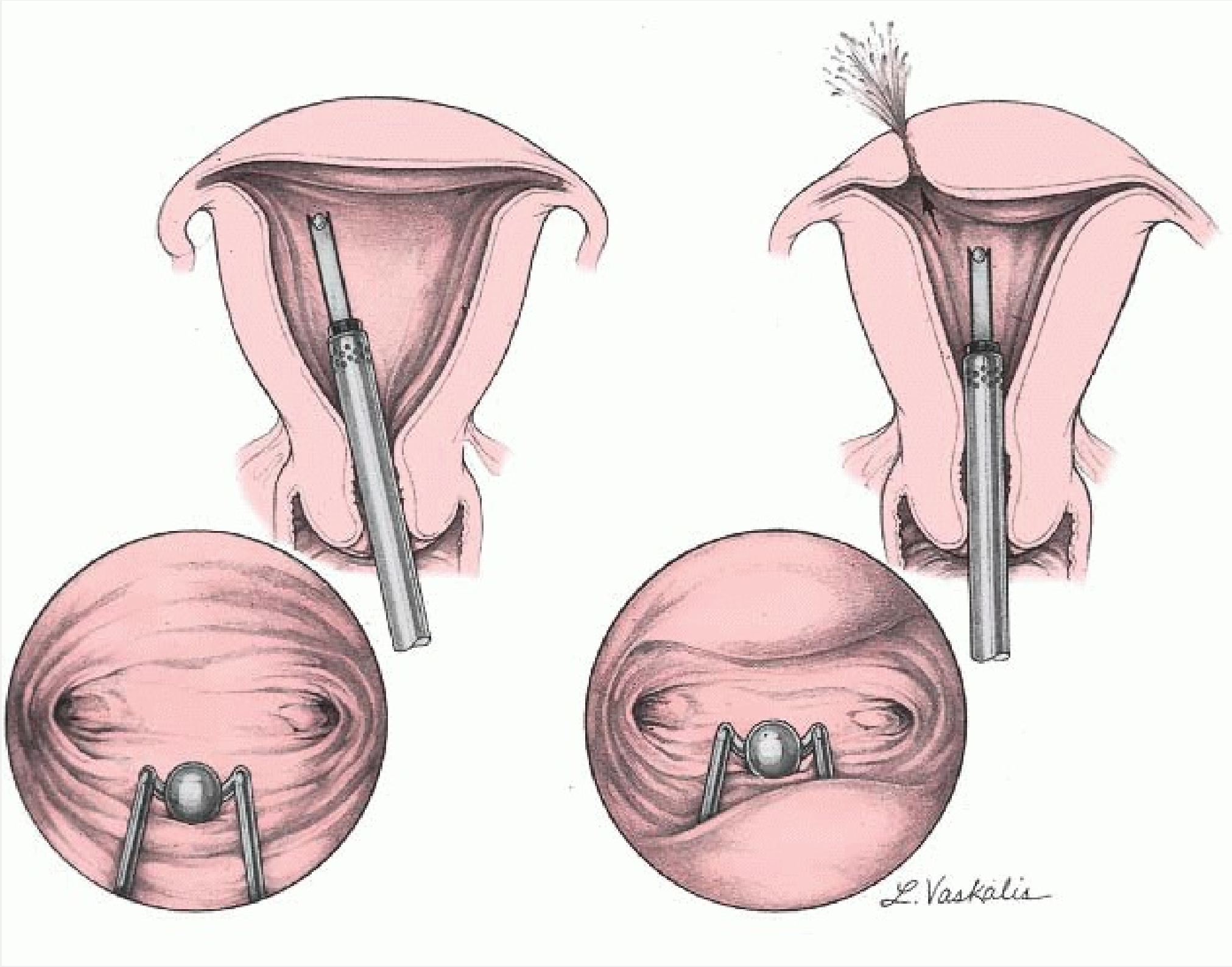

FIGURE 18.32 Perforation should be immediately suspected when the endometrial cavity depressurizes and collapses around the hysteroscope, creating a compromised view of the cavity. (Baggish MS, Valle RF, Guedj H. *Hysteroscopy: visual perspectives of uterine anatomy, physiology and pathology,* 3rd ed. Philadelphia, PA: Lippincott Williams & Wilkins, 2007, with permission.)

Methods to prevent fluid overload include the following: (a) Use isotonic fluids such as normal saline whenever possible, (b) monitor the fluid deficit closely, (c) maintain intrauterine fluid pressure at 70 to 80 mm Hg, and (d) limit surgical operating time to 1 hour or less. Serious complications due to hyponatremia have been reported from use of hypoosmolar fluids such as sorbitol and glycine. For instance, absorption of 1,000 mL of glycine distension medium during hysteroscopy is associated with a reduction in serum sodium of approximately 10 mEq/L. The American Congress of Obstetricians and Gynecologists' Committee on Gynecologic Practice recommends termination of a case with a deficit of 750 mL with hypoosmolar fluids when patient is elderly or has comorbid conditions. The case should be terminated for a deficit of 1,000 to 1,500 mL for all other patients. When an isotonic distension medium is used, the case should be terminated when the deficit reaches 2,500 mL. With this finding, in addition to terminating the case, a stat sodium level should be sent and patient should be administered a loop diuretic such as furosemide. Severe hyponatremia should be managed in cooperation with an intensive care specialist; the patient should be very closely monitored and may require hypertonic saline.

Poor Visibility in the Operative Field

Inability to see the operative field is a common problem. The usual cause of this problem is deep insertion of the hysteroscope so that the telescope lies directly in contact with the endometrium. The surgeon will see nothing but a red blur. The natural tendency is to push the hysteroscope deeper in. This strategic mistake invariably leads to perforation. Another cause of visibility problems is blood within the uterine cavity secondary to dilatation. The fastest way to deal with a bloody cavity is rapid flushing with the hysteroscopic medium combined with aspiration using a cannula placed into the cavity via the operating channel.

Overdilatation of the cervix is an equally common mistake that results in excessive leakage of distending medium and an inability to maintain distension, with the resultant inability to perform the operative hysteroscopy. Blood and debris can cloud the field to such a degree that accurate operative endoscopy is impossible. If the operator cannot clearly see the field, it is better to discontinue the procedure rather than press on and risk a catastrophic error. It is easy to become disoriented in the uterine cavity if normal anatomic landmarks cannot be recognized.

Gas Embolus

Gas embolism is a well-documented complication of operative hysteroscopy using CO_2 as the distending medium, with a 0.51% incidence of subclinical events and a 0.03% incidence of symptomatic events in a review of 3,932 cases by Brandner et al. As previously mentioned, a fatal CO_2 gas embolism is especially likely to occur if a laparoscopic CO_2 insufflator is connected to the diagnostic hysteroscope.

Air embolism may also occur commonly during operative hysteroscopy when fluid distending media are used, with an incidence from 10% to 50% having been reported. Differences in incidence rates are most likely due to differences in methods used to detect embolization. Methods include noticing a decrease in end-tidal CO_2, which is not very specific, and detecting a millwheel murmur. Transesophageal echocardiography appears to be the most sensitive and specific monitoring method. Introduction of ambient air into the uterine cavity by repeated passes of the hysteroscope or by creation of vapors by use of electrosurgery is thought to be responsible for causing air emboli. Air then passes into venous sinuses of the uterus either passively or actively from the pressure of the liquid media. If a gas embolism is suspected, the procedure should be stopped immediately. Avoiding the Trendelenburg position during operative hysteroscopy has been suggested to decrease the risk of gas embolism.

Infection

Infection is an unlikely complication associated with hysteroscopy. Hysteroscopy should be avoided in the presence of gross cervical infection, uterine infection, or salpingitis. Infection is otherwise uncommon after even extensive intrauterine surgery (e.g., adhesiotomy or myomectomy). Prophylactic antibiotics should be administered only when indications exist such as a history of rheumatic carditis, congenital heart defect, or prolapsed mitral valve or in cases of suspected chronic endometritis (submucous myoma or imbedded IUD). Baggish and colleagues in 1999 observed only 13 infections out of 5,000 cases that could be casually related to the hysteroscopic operation. Salat-Baroux and associates reported 7 mild infections out of 4,000 hysteroscopic examinations. On the other hand, McCausland and coworkers reported three cases of tuboovarian abscess after operative hysteroscopy. Agostini and colleagues reported 30 infections associated with 2,116 operative hysteroscopies. Eighteen of these infections were cases of endometritis.

Operator Technique

The most serious complications happen because of operator error. Most often, these are the result of inexperience and are avoidable. Difficult cases beyond the capabilities of the primary care gynecologist should be referred to the expert hysteroscopist. Skill in one area of endoscopy (e.g., operative laparoscopy) does not confer similar expertise in operative hysteroscopy. Indeed, the opposite may be truer.

During the postoperative period, operative complications should be the initial exclusion diagnosis for any patient who is not recovering according to the usual pattern. Worsening postoperative pain, fever, nausea, distension, and free intraperitoneal air are the signals of bowel injury. Diminished urinary output, fever, and distension suggest bladder or ureteral trauma. Falling blood pressure and rapid thready pulse, with or without distension, should raise concerns of a vascular problem and third-space hemorrhage.

Most negligence cases adjudicated in favor of the plaintiff have involved delayed initiation of appropriate treatment for an operative complication. Cases involving injury recognized at the time of surgery and correctly managed in a timely fashion do not usually become medicolegal problems.

Equipment Failure

As previously reviewed in this chapter, diagnostic and operative hysteroscopic procedures utilize complex equipment requiring attention for correct instrument assembly, connection to electrical or laser energy sources as well as connections to video cameras and monitors for proper administration of distending media. In a recent prospective observation study by Courdier, equipment failures were divided into four categories: imaging, transmission of fluids and light, the electric circuit, and surgical instruments. During 51 operative hysteroscopies, 37.3% (19) were complicated by equipment failures. Most common problems included nonavailable or damaged hysteroscopic connections and fittings, faulty connections, or an incorrect setting of the suction system. Surgeon error and staff error contributed to many of the documented errors. Surgeons performing diagnostic and operative hysteroscopy should be able to assemble and disassemble the hysteroscopic instruments, be able to connect and activate the video monitoring systems, and be capable of operating the hysteroscopic fluid monitoring systems. Creation of checklists for surgeons and assistants to review prior to performing the hysteroscopic procedure may be of value.

BEST SURGICAL PRACTICES

- Abnormal uterine bleeding is most comprehensively evaluated by hysteroscopy and sampling as opposed to blind curettage.
- A gynecologist or gynecologist-in-training can best learn hysteroscopy by performing 25 to 50 diagnostic hysteroscopies before initiating operative procedures.
- Infusion of liquid, low-viscosity media during operative hysteroscopy must be accurately measured and recorded, especially hypoosmolar media such as glycine or sorbitol.
- Perforation during operative hysteroscopy with an energy device requires laparotomy to inspect intraabdominal structures for thermal injury.
- A clear, unobstructed view of the intrauterine milieu is necessary before the initiation of any endouterine surgery.

BIBLIOGRAPHY

AAGL Advancing Minimally Invasive Gynecology Worldwide; Munro MG, Storz K, Abbott JA, et al. AAGL Practice Report: Practice Guidelines for the Management of Hysteroscopic Distending Media. *J Minim Invasive Gynecol* 2013;20:137.

Aberdeen Endometrial Ablation Trials Group. A randomized trial of endometrial ablation versus hysterectomy for the treatment of dysfunctional uterine bleeding: outcome at four years. *Br J Obstet Gynaecol* 1999;106:360.

Agostini A, Cravello L, Desbriere R, et al. Hemorrhage risk during operative laparoscopy. *Acta Obstet Gynecol Scand* 2002;81:878.

Agostini A, Cravello L, Shojai R, et al. Postoperative infection and surgical hysteroscopy. *Fertil Steril* 2002;77:766.

Alborzi S, Dehbashi S, Parsanezhad ME. Differential diagnosis of septate and bicornuate uterus by sonohysterography eliminates the need for laparoscopy. *Fertil Steril* 2002;78:176.

Aydeniz B, Gruber IV, Schauf B, et al. A multicenter survey of complications associated with 21,676 operative hysteroscopies. *Eur J Obstet Gynecol Reprod Biol* 2002;104:160.

Baggish MS, Barbot J, Valle RF. *Diagnostic and operative hysteroscopy: a text and atlas.* Chicago, IL: Mosby-Year Book, 1989.

Baggish MS, Barbot J, Valle RF. *Diagnostic and operative hysteroscopy,* 2nd ed. St. Louis, MO: Mosby-Year Book, 1999, Lippincott Williams & Wilkins, 2007.

Baggish MS, Brill AI, Rosenzweig B, et al. Fatal acute glycine and sorbitol toxicity during operative hysteroscopy. *J Gynecol Surg* 1993;9:137.

Baggish MS, Sze EHM. Experience with 568 endometrial ablation procedures. *J Gynecol Surg* 1996;174:908.

Baggish MS, Sze EHM, Morgan G. Hysteroscopic treatment of symptomatic submucous myomata uteri with the Nd-YAG laser. *J Gynecol Surg* 1989;5:127.

Baggish MS, Valle RF, Guedj H. *Hysteroscopy: visual perspectives of uterine anatomy, physiology and pathology,* 3rd ed. Philadelphia, PA: Lippincott Williams & Wilkins, 2007.

Brink DM, DeJong P, Fawcus S, et al. Carbon dioxide embolism following diagnostic hysteroscopy. *Br J Obstet Gynaecol* 1994;101:717.

Brandner P, Neis KJ, Ehmer C. The etiology, frequency, and prevention of gas embolism during CO(2) hysteroscopy. *J Am Assoc Gynecol Laparosc* 1999;6:421.

Brundin J, Thomasson K. Cardiac gas embolism during carbon dioxide hysteroscopy: risk and management. *Eur J Obstet Gynecol Reprod Biol* 1989;33:241.

Cameron IM, Mollison J, Pinion SB, et al. A cost comparison of hysterectomy and hysteroscopic surgery for the treatment of menorrhagia. *Eur J Obstet Gynecol Reprod Biol* 1996;70:87.

Capella-Allouc S, Morsad F, Rongieres-Bertrand C, et al. Hysteroscopic treatment of severe Asherman's syndrome and subsequent fertility. *Human Reprod* 1999;14:1230.

Cararach M, Penella J, Ubeda A, et al. Hysteroscopic incision of the septate uterus: scissors versus resectoscope. *Hum Reprod* 1994;9:87.

Ceci O, Bettocchi S, Marello F, et al. Hysteroscopic evaluation of the endometrium in postmenopausal women taking tamoxifen. *J Am Assoc Gynecol Laparosc* 2000;7:185.

Christianson MS, Barker MA, Lindheim SR. Overcoming the challenging cervix: techniques to access the uterine cavity. *J Low Genit Tract Dis* 2008;12:24.

Clark TJ, Mahajan D, Sunder P, et al. Hysteroscopic treatment of symptomatic submucous fibroids using a bipolar intrauterine system: a feasibility study. *Eur J Obstet Gyn Reprod Biol* 2002;100:237.

Corson SL, Brooks PG, Soderstrom RM. Gynecologic endoscopic gas embolism. *Fertil Steril* 1996;65:529.

Courdier S, Garbin O, Hummel M, et al. Equipment failure: causes and consequences in endoscopic gynecologic surgery. *J Minim Invasive Gynecol* 2009;16:28.

Creinin M, Chen M. Uterine defect in a twin pregnancy with a history of hysteroscopic fundal perforation. *Obstet Gynecol* 1992;79:879.

Dumesic DA, Dhillon SS. A new approach to hysteroscopic cannulation of the fallopian tube. *J Gynecol Surg* 1991;7:7.

Dwyer N, Hutton J, Stirkat GM. Randomized controlled trial comparing endometrial resection with abdominal hysterectomy for surgical treatment of menorrhagia. *Br J Obstet Gynaecol* 1993;100:237.

Emanuel MH, Wamsteker K, Hart AA, et al. Long-term results of hysteroscopic myomectomy for abnormal uterine bleeding. *Obstet Gynecol* 1999;93:743.

Fisher JC. Principles of safety in laser surgery and therapy. In: Baggish MS, ed. *Basic and advanced laser surgery in gynecology.* Norwalk, CT: Appleton-Century-Crofts, 1985:85.

Friedler S, Margalioth EJ, Kafka I, et al. Incidence of post-abortion intrauterine adhesions evaluated by hysteroscopy: a prospective study. *Hum Reprod* 1993;8:442.

Gabriele A, Zanetta G, Pasta F, et al. Uterine rupture after hysteroscopic metroplasty and labor induction. *J Reprod Med* 1999;44:642.

Garry R, Hasham F, Kokri MS, et al. The effect of pressure of fluid absorption during endometrial ablation. *J Gynecol Surg* 1992;8:1.

Garry R, Shelley-Jones D, Mooney P, et al. Six hundred endometrial laser ablations. *Obstet Gynecol* 1995;85:24.

Garuti G, Cellani F, Colonnelli M, et al. Hysteroscopically targeted biopsies compared with blind samplings in endometrial assessment of menopausal women taking tamoxifen for breast cancer. *J Am Assoc Gynecol Laparosc* 2004;11:62.

Gebauer G, Hafner A, Siebzehnrubl E, et al. Role of hysteroscopy in detection and extraction of endometrial polyps: results of a prospective study. *Am J Obstet Gynecol* 2002;186:1104.

Goldenberg M, Zolti M, Seidman DS, et al. Transient blood oxygen desaturation, hypercapnia and coagulopathy after operative hysteroscopy with glycine used as the distending medium. *Am J Obstet Gynecol* 1994;170:25.

Goldrath MH. Vaginal removal of the pedunculated submucous myoma: the use of laminaria. *Obstet Gynecol* 1987;70:670.

Goldrath MH, Fuller T, Segal S. Laser photovaporization of endometrium for the treatment of menorrhagia. *Am J Obstet Gynecol* 1981;140:14.

Gonzales R, Brensilver JM, Rovinsky JJ. Post-hysteroscopic hyponatremia. *Am J Kidney Dis* 1994;23:735.

Groenman FA, Peters LW, Rademaker BM, et al. Embolism of air and gas in hysteroscopic procedures: pathophysiology and implication for daily practice. *J Minim Invasive Gynecol* 2008;15:241.

Halverson LM, Aserkoff RD, Oskowitz SP. Spontaneous uterine rupture after hysteroscopic metroplasty with uterine perforation. *J Reprod Med* 1993;38:236.

Hidlebaugh DA, Orr RK. Long-term economic evaluation of resectoscopic endometrial ablation versus hysterectomy for the treatment of menorrhagia. *J Am Assoc Gynecol Laparosc* 1998;5:351.

Howe RS. Third trimester uterine rupture following hysteroscopic uterine perforation. *Obstet Gynecol* 1993;81:827.

American Congress of Obstetricians and Gynecologists. Technology Assessment in Obstetrics and Gynecology No. 7: hysteroscopy. *Obstet Gynecol* 2011;117:1486.

Istre O, Skajaa K, Schjoensby AP, et al. Changes in serum electrolytes after transcervical resection of endometrium and submucous fibroids with use of glycine 1.5% for uterine irrigation. *Obstet Gynecol* 1992;80:218.

Jansen FW, Vredevoogd CB, van Ulzen K, et al. Complications of hysteroscopy: a prospective, multicenter study. *Obstet Gynecol* 2000;96:266.

Jones HW, Seegar-Jones G. Double uterus as an etiological factor in repeated abortion: indications for surgical repair. *Am J Obstet Gynecol* 1953;65:325.

Kivnick S, Kanter MH. Bowel injury from rollerball ablation of the endometrium. *Obstet Gynecol* 1992;79:833.

Lefler HT Jr. Long-term follow-up of endometrial ablation by modified loop resection. *J Am Assoc Gynecol Laparosc* 2003;10:517.

Lin BL, Iwata Y, Liu KH, Valle RF. Clinical applications of a new Fujinon operating fiberoptic hysteroscope. *J Gynecol Surg* 1990;6:81.

Litta P, Pozzan C, Merlin F, et al. Hysteroscopic metroplasty under laparoscopic guidance in infertile women with septate uteri: follow-up of reproductive outcome. *J Reprod Med* 2004;49:274.

Lobaugh ML, Bammel BM, Duke D, et al. Uterine rupture during pregnancy in a patient with a history of hysteroscopic metroplasty. *Obstet Gynecol* 1994;83:838.

MacLean-Fraser E, Penava D, Vilos GA. Perioperative complication rates of primary and repeat hysteroscopic endometrial ablations. *J Am Assoc Gynecol Laparosc* 2002;9:175.

Magos AL, Baumann R, Lockwood GM, et al. Experience with the first 250 endometrial resections for menorrhagia. *Lancet* 1991;337:1074.

March CM. Hysteroscopy for infertility in diagnostic and operative hysteroscopy. In: Baggish MS, Barbot J, Valle RF, eds. *Diagnostic and operative hysteroscopy: a text and atlas.* Chicago, IL: Mosby-Year Book, 1989:136.

March CM, Israel R. Gestational outcome following hysteroscopic lysis of adhesions. *Fertil Steril* 1981;36:455.

March CM, Israel R. Hysteroscopic management of recurrent abortion caused by septate uterus. *Am J Obstet Gynecol* 1987;156:834.

March CM, Israel R, March AD. Hysteroscopic management of intrauterine adhesions. *Am J Obstet Gynecol* 1978;130:65.

Mints M, Radestad A, Rylander E. Follow up of hysteroscopic surgery for menorrhagia. *Acta Obstet Gynecol Scand* 1998;77:435.

Neuwirth RS. Hysteroscopic management of symptomatic submucous fibroids. *Obstet Gynecol* 1983;62:509.

Neuwirth RS. Hysteroscopic resection of submucous leiomyoma. *Contemp Obstet Gynecol* 1985;25:103.

Neuwirth RS. A new technique for and additional experience with hysteroscopic resection of submucous fibroids. *Am J Obstet Gynecol* 1978;131:91.

Neuwirth RS, Amin HK. Excision of submucous fibroids with hysteroscopic control. *Am J Obstet Gynecol* 1976;126:95.

Novy MJ, Thurmond AS, Patton P, et al. Diagnosis of cannula obstruction by transcervical fallopian tube cannulation. *Fertil Steril* 1988;50:434.

Obermair A, Geramou M, Gucer F, et al. Does hysteroscopy facilitate tumor cell dissemination? Incidence of peritoneal cytology from patients with early stage endometrial carcinoma following dilatation and curettage (D & C) versus hysteroscopy and D & C. *Cancer* 2000;88:139.

Overton C, Hargreaves J, Maresh M. A national survey of complications of endometrial destruction for menstrual disorders: the Mistletoe study. *Br J Obstet Gynaecol* 1997;104:1351.

Pabuccu R, Gomel V. Reproductive outcome after hysteroscopic metroplasty in women with septate uterus and otherwise unexplained infertility. *Fertil Steril* 2004;81:1675.

Pantaleoni D. On endoscopic examination of the cavity of the womb. *Med Press Circ* 1869;8:26.

Patton PE, Novy MJ. The diagnosis and reproductive outcome after surgical treatment of the complete septate uterus, duplicated cervix and vagina septum. *Am J Obstet Gynecol* 2004;190:1669.

Perlitz Y, Rahav D, Ben-Ami M. Endometrial ablation using hysteroscopic instillation of hot saline solution into the uterus. *Eur J Obstet Gynecol Reprod Biol* 2001;99:90.

Perry CP, Daniell JF, Gimpelson RJ. Bowel injury from Nd-YAG endometrial ablation. *J Gynecol Surg* 1990;6:199.

Perry PM, Baughman VL. A complication of hysteroscopy: air embolism. *Anesthesiology* 1990;73:546.

Propst AM, Liberman RF, Harlow BL, et al. Complications of hysteroscopic surgery: predicting patients at risk. *Obstet Gynecol* 2000;96:517.

Quinones RG. Hysteroscopy with a new fluid technique. In: Siegler AM, Lindemann HJ, eds. *Hysteroscopy: principles and practice.* Philadelphia, PA: JB Lippincott Co., 1984:41.

Reed TP, Erb RA. Hysteroscopic tubal occlusion with silicone rubber. *Obstet Gynecol* 1983;61:388.

Roberts S, Long L, Jonasson O. The isolation of cancer cells from the bloodstream during uterine curettage. *Surg Gynecol Obstet* 1960;111:3.

Rock JA, Singh M, Murphy A. A modification of technique for hysteroscopic lysis of severe uterine adhesions. *J Obstet Gynecol* 1993;9:191.

Rogerson L, Gannon MJ, Donovan PJ. Outcome of pregnancy following endometrial ablation. *J Gynecol Surg* 1997;13:155.

Romer T. Benefit of GnRH analogue pretreatment for hysteroscopic surgery in patients with bleeding disorders. *Gynecol Obstet Invest* 1998;45(suppl 1):12.

Ruiz JM, Neuwirth RS. The incidence of complications associated with the use of Hyskon during hysteroscopy: experience in 1793 consecutive patients. *J Gynecol Surg* 1992;8:219.

Salat-Baroux J, Hamou JE, Maillard G, et al. Complications from micro-hysteroscopy. In: Siegler A, Lindemann H, eds. *Hysteroscopy.* Philadelphia, PA: JB Lippincott Co., 1984.

Saygili-Yilmaz E, Yildiz S, Erman-Akar M, et al. Reproductive outcome of septate uterus after hysteroscopic metroplasty. *Arch Gynecol Obstet* 2003;268:289.

Schmitz MJ, Nahhas WA. Hysteroscopy may transport malignant cells into the peritoneal cavity: case report. *Eur J Gynaecol Oncol* 1994;15:121.

Selk A, Kroft J. Misoprostol in operative hysteroscopy: a systematic review and meta-analysis. *Obstet Gynecol* 2011;118:941.

Siegler AM, Kemmann EK. Hysteroscopic removal of occult intrauterine contraceptive device. *Obstet Gynecol* 1975;46:604.

Siegler AM, Kemmann EK. Hysteroscopy: a review. *Obstet Gynecol Surg* 1975;30:567.

Smith DC, Donohue LR, Waszak SJ. A hospital review of advanced gynecologic endoscopic procedures. *Am J Obstet Gynecol* 1994;170:1635.

Soucie JE, Chu PA, Ross S, et al. The risk of diagnostic hysteroscopy in women with endometrial cancer. *Am J Obstet Gynecol* 2012;207:71.e1.

Sowter MC, Singla AA, Lethaby A. Pre-operative endometrial thinning agents before hysteroscopic surgery for heavy menstrual bleeding. *Update in Cochrane Database Syst Rev* 2002;(3):CD001 124;PMID:12137619

Strassman EO. Plastic unification of double uterus. *Am J Obstet Gynecol* 1952;64:25.

Sullivan B, Kenney P, Seibel M. Hysteroscopic resection of fibroid with thermal injury to sigmoid. *Obstet Gynecol* 1992;80:546.

Taponeco F, Curcio C, Fasciani A, et al. Indication of hysteroscopy in tamoxifen treated breast cancer. *J Exp Clin Cancer Res* 2002; 21:37.

Tapper AM, Heinonen PK. Experience with isotonic 2.2% glycine as distension medium for hysteroscopic endomyometrial resection. *Gynecol Obstet Invest* 1999;47:263.

Valle RF. Hysteroscopic evaluation of patients with abnormal uterine bleeding. *Surg Gynecol Obstet* 1981;153:521.

Valle RF. Hysteroscopic removal of submucous leiomyomas. *J Gynecol Surg* 1990;6:89.

Valle RF. Hysteroscopy for gynecologic diagnosis. *Clin Obstet Gynecol* 1983;26:253.

Valle RF, Sciarra JJ. Hysteroscopy: a useful diagnostic adjunct in gynecology. *Am J Obstet Gynecol* 1975;122:230.

Valle RF, Sciarra JJ, Freeman DW. Hysteroscopic removal of intrauterine devices with missing filaments. *Obstet Gynecol* 1977;49:55.

Vilos GA. Intrauterine surgery using a new coaxial bipolar electrode in normal saline solution (Versapoint): a pilot study. *Fertil Steril* 1999;4:740.

Yaron Y, Shenhav M, Jaffa AJ, et al. Uterine rupture at 33 weeks' gestation subsequent to hysteroscopic uterine perforation. *Am J Obstet Gynecol* 1994;170:786.

Zerbe MJ, Zhang J, Bristow RE, et al. Retrograde seeding of malignant cells during hysteroscopy in presumed early endometrial cancer. *Gynecol Oncol* 2000;79:55.

Zikopoulos KA, Kolibianakis EM, et al. Live delivery rates in subfertile women with Asherman's syndrome after hysteroscopic adhesiolysis using the resectoscope or the Versapoint system. *Reprod Biomed Online* 2004;8:720.